

## Male incontinence and the transobturator approach: An analysis of current outcomes

Salvatore Siracusano, Francesco Visalli & Laura Toffoli

To cite this article: Salvatore Siracusano, Francesco Visalli & Laura Toffoli (2013) Male incontinence and the transobturator approach: An analysis of current outcomes, Arab Journal of Urology, 11:4, 331-335, DOI: [10.1016/j.aju.2013.06.008](https://doi.org/10.1016/j.aju.2013.06.008)

To link to this article: <https://doi.org/10.1016/j.aju.2013.06.008>



© 2013 Arab Association of Urology



Published online: 05 Apr 2019.



Submit your article to this journal [↗](#)



Article views: 205




View related articles [↗](#)



**Arab Journal of Urology**  
(Official Journal of the Arab Association of Urology)

[www.sciencedirect.com](http://www.sciencedirect.com)



**VOIDING DYSFUNCTION / FEMALE UROLOGY**  
**REVIEW**

**Male incontinence and the transobturator approach: An analysis of current outcomes**



**Salvatore Siracusano \***, Francesco Visalli, Laura Toffoli

Department of Urology, Trieste University, Ospedale di Cattinara, Via Strada di Fiume 447, 34100 Trieste, Italy

Received 27 February 2013, Received in revised form 5 May 2013, Accepted 21 June 2013  
Available online 29 September 2013

**KEYWORDS**

Male;  
Postoperative incontinence;  
Transobturator sling

**ABBREVIATIONS**

RP, radical prostatectomy;  
SUI, stress urinary incontinence;  
AUS, artificial urinary sphincter

**Abstract Objectives:** To provide an analysis of the outcomes in patients who have a suburethral sling placed using the transobturator approach for the treatment of stress urinary incontinence after radical prostatectomy, because data in this specific area remain limited, and recent changes in male sling surgery might improve the efficacy in men with moderate or mild incontinence.

**Methods:** We evaluated the results of transobturator non-adjustable and re-adjustable sling systems after reviewing previous reports identified using the Medline and PubMed databases for original articles, from 2002 to 2012, using the terms ‘postoperative male incontinence’, ‘transobturator’ and ‘male sling’. Of a total of 31 articles, we reviewed the 22 related to the outcomes of the suburethral sling with positioning by the transobturator approach.

**Results:** Currently the only results of the transobturator approach are those relating to the AdVance™ device (American Medical Systems, Minnetonka, MN, USA), for which the cure rate is  $\approx 60\%$  at 20 months. The remaining devices, although innovative, were assessed in studies for which the follow-up was too short to make a judgement.

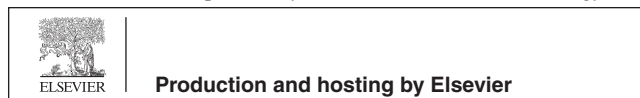
**Conclusions:** It would be advisable to reserve the transobturator approach for patients with mild and moderate incontinence, and refer those with severe incontinence, with or without adjuvant radiotherapy after radical prostatectomy, for treatment with an artificial urinary sphincter. More results and a long-term follow-up are needed to evaluate the effectiveness of these devices.

© 2013 Production and hosting by Elsevier B.V. on behalf of Arab Association of Urology.

\* Corresponding author. Tel.: +39 040399 4897.

E-mail address: [siracus@units.it](mailto:siracus@units.it) (S. Siracusano).

Peer review under responsibility of Arab Association of Urology.



## Introduction

Although surgical techniques for radical prostatectomy (RP) have been refined extensively during the last 20 years, significantly many patients still have persistent stress urinary incontinence (SUI) after RP [1,2]. Such SUI often has an important effect on the quality of life of those affected. The artificial urinary sphincter (AUS) has become the standard option for treating this disorder, but it is expensive and associated with mechanical failure. Despite the success of AUS there has been a renewed interest in male slings. Current male sling devices are based on the early concepts described by Berry [3], Kaufman [4] and Kishev [5] in the 1960s and early 1970s. Most notable were the Kaufman procedures, which included a crural crossover [6], and they were then modified to use a synthetic mesh tape that brings the crura together in the midline [4] using a silicone-gel device attached to the corpora cavernosa and that compresses the ventral urethra. Based on the Kaufman principles, Clemens et al. [7] reported a bulbourethral sling procedure in 64 men with severe SUI after RP. With a series of PTFE bolsters placed beneath the bulbar urethra, through which a suture is passed and then transferred suprapubically using a Stamey needle lateral to the urethra and bladder neck, this provided compression of the bulbar urethra. At a mean follow-up of 18 months, 56% of patients became continent and 8% improved significantly. However, despite the encouraging results, a sling revision was required in 21% of patients and the bolster required removal, secondary to infection, in 6%. Moreover, 52% of patients had perineal numbness or pain, with 26% rating this problem as moderate or severe. This discomfort was most likely due to the high-pressure entrapment of pudendal nerve branches during the ‘blind’ suprapubic suture or passage. Therefore, to avoid discomfort, special sling systems were devised to make this surgical approach even less invasive and much safer.

All currently marketed slings for the minimally invasive treatment of male incontinence induce compression or suspension of the bulbar urethra, as recently described by Rehder et al. [8]. At present, a long-term follow-up of these procedures is lacking, even though the European Association of Urology guidelines assigned a grade of recommendation at level C and with level of evidence 3 [1].

## Methods

In this review we discuss the results of transobturator non-adjustable and re-adjustable sling systems by assessing previous reports that were identified using the Medline and PubMed databases for original articles published from 2002 to 2012, using the terms ‘postoperative male incontinence’, ‘transobturator’ and ‘male sling’. In particular we analysed 31 articles reporting the current guidelines and outcomes on the surgical transobturator approaches. Of these, 16 studies relate

to the AdVance™ device (American Medical Systems, Minnetonka, MN, USA), two to the TOMS device (Genesis Medical Ltd, London, UK), two to the de Leval sling, and one report each to the Argus T (Promedon, Córdoba, Argentina) and ATOMS device (AMI GmbH, Feldkirch, Austria), respectively.

## Non-adjustable slings, ‘outside in’

### *AdVance*

Different compressive sling systems were evaluated for many years and the AdVance was the first sling with a functional therapeutic approach. This new sling merely repositioned the lax and descended supporting structures of the sphincter to their former preoperative position [8]. The retro-urethral transobturator sling offers a non-compressive functional therapeutic approach to the membranous urethra, by fixing it into the normal anatomical position, thus allowing the normal function of the sphincter. This sling has been shown to be ineffective in patients with intrinsic sphincter deficiency [8]. Urodynamic studies show an increase in the membranous urethral length and an improvement in the urethral closure pressure, with no obstruction [8].

### *The surgical procedure*

The procedure used was essentially that described previously [8–10] and in the short-term was effective in ≈70% of patients at a median follow-up of 19 months (Table 1 [11–19]). The first results were reported by Rehder et al. [8], and confirmed by Gozzi et al. [11], who showed cure and improvement rates of 52% and 38%, respectively, with low morbidity after a 6-month follow-up.

These results were corroborated by Bauer et al. [12], who reported a cure rate of 51.4%, an improvement rate of 25.7% and a failure rate of 22.9% in 70 men followed up for 12 months.

Cornel et al. [13] reported poor results with the AdVance sling, with only a 9% cure rate at 12 months and an overall improvement in 45.5% of men. Recently Gill

**Table 1** Outcomes of using the AdVance transobturator sling system.

Reference	No. of patients	Mean follow-up (months)	% Cure	% Improved
[11]	67	6	52	38
[12]	70	12	51.4	25.7
[13]	36	12	9	–
[14]	33	9	60	–
[15]	136	21	62	16
[16]	66	24	53.6	–
[17]	156	36	76.8	23.2
[18]	137	27	51.6	23.8
[19]	61	26	80	–

et al. [14], in a retrospective chart review and telephone interview, reported satisfactory results in 33 men, with an objective success rate of 60% and a pad free-rate of 28.5% at 9 months. All these results show the wide variability in the concept of success or healing, as seen by Cornu et al. [15], who described an overall success rate of 62% at 21 months, but with criteria different from those reported by Davies et al. [20], who evaluated the success rate based on a 24-h pad test and urodynamic changes induced by the sling at a mean follow-up of 6 months.

Urinary retention was usually rare. Cornel et al. [13] reported transient retention in 3% of patients, while Gill et al. [14] found three men with retention and two who needed to catheterise for 3 and 6 months, respectively. By contrast, Bauer et al. [21] reported transient postoperative urinary retention in 21% of patients, which was resolved within the first 3 months. Finally, Bauer et al. [21] also reported the need to remove the sling in 0.9% of patients with severe and permanent urinary obstruction. In the study of Cornel et al. [13], 17% of men had severe postoperative pain that settled at 3 months, but otherwise pain was rarely reported.

Recently Li et al. [16] and Rehder et al. [17] reported interesting results at the 2- and 3-year follow-up, respectively. In particular, Li et al. reported a success rate of 53.6% in 66 patients, concluding that most of them reported an improvement in SUI but with a decrease in the benefit with time. However, these results were not confirmed by Rehder et al. in a multicentre study, describing a success rate of 76.9% at 12 months that was maintained at 3 years, at 76.8%. This trend reported by Rehder et al. was also described by Bauer et al. [18], with an overall rate of 75.4% in 137 patients at a median follow-up of 27 months, and recently confirmed by Serra et al. [19], who reported satisfactory results in men with mild SUI.

## TOMS

In 2006 Grise developed a new transobturator bulbar male sling [22] that works by compressing the urethra in a more distal position than does the AdVance sling. At the 12-month follow-up Grise et al. [23] reported a reduction of pad use in 30% of patients, with a concomitant improvement in quality of life. In particular, the Short-Form 36 continence scores improved significantly from a median (95% CI) of 100 (83–133) to 300 (167–375) at 1 year, as the incontinence score decreased significantly from 15 (14–16) before the TOMS sling to 8 (5–12) at 1 year of follow-up.

### Non-adjustable slings, 'inside out'

#### *de Leval sling*

In 2008 de Leval reported on a new transobturator polypropylene sling [24], with two arms passed inside-out

through the obturator foramen, pulled for compressing the urethral bulb, and tied to each other across the midline. Conceptually this approach was designed to minimise the risk of penetrating the pelvic space and perforating the urethra by the trocars and mesh arms, lessen the possibility of urethral erosion by using a large mesh entirely covering the bulbospongiosus muscle, and by avoiding fixation of the mesh to the urethra with suture material, and sustain sling tension by tying up the mesh arms to prevent mesh slippage.

### *Outcomes*

At a mean follow-up of 24 months, the cure and improvement rates were 49% and 35%, respectively, and the failure rate was 16%. There were no sling infections, persistent pain, bladder, urethra, bowel, or nerve complications [24]. Recently the authors reported the mid-term results from 173 consecutive patients [25]. After a median follow-up of 24 months, 49% were cured, 35% improved and 16% not improved. The quality-of-life score was increased and 72% of patients were moderately to completely satisfied with the procedure.

### Adjustable slings

#### *Argus T*

The Argus T is a re-adjustable suburethral sling device which allows an effective regulation of the sling tension not only during surgery but also in the first few days after surgery. This option for controlling the suburethral pressure is the main advantage of this procedure for curing incontinence and avoiding urinary retention.

The Argus T system is composed of a radio-opaque cushioned system with silicone foam, for soft bulbar urethral compression, two silicone columns formed by multiple conical elements, which are attached to the pad and allow system readjustment, and two radio-opaque silicone washers which allow regulation of the sling tension.

In patients with mild to moderate incontinence, continence rates of up to 70% were reported after a median follow-up of 6 months in 37 patients [26]. In that study Romano et al. reported a 73% cure rate, a 13.5% improvement rate, and the treatment failed in five patients (13.5%).

#### *ATOMS*

This sling was developed in 2005 [27] and introduced in Europe in 2008, being implanted for the first time in March 2009. The advantages of this device are the option for postoperative adjustment with no surgical re-intervention, and the low possibility of dislocation.

The ATOMS system consists of a mesh implant with an integrated adjustable cushion, protection sheet and titanium pot for adjusting the cushion volume. The

silicone cushion is located in the middle of the mesh and filled via the port and catheter during or after surgery. The adjustment is made by puncturing the port percutaneously, and it is possible at any time in an outpatient setting to counteract continued incontinence or urinary retention.

At present results are only reported in the short term, and at a mean follow-up of 16.9 months, Seweryn et al. [28] reported an overall success rate of 84% (61% dry, 24% improved), with failure in only 16% of the patients. Hoda et al. [29], at a mean follow-up of 17.8 months, reported an overall success rate of 92% (63% dry, 29% improved) with an 8% failure rate.

## Conclusions

Advances in surgical techniques for general incontinence have led to new alternatives for managing incontinence after RP. It is generally accepted that patients with mild to moderate incontinence are appropriate candidates for a male sling, and probably those with severe incontinence should be treated with an AUS, although there is no specific recommendation in this context. In particular, we believe that it would be advisable to treat urinary incontinence with an AUS in patients undergoing adjuvant radiotherapy, and to reserve the choice of the sling for those with mild and moderate urinary incontinence with no previous radiotherapy. It is likely that in patients who have had previous radiotherapy, the bulbo-urethral fibrosis would make it more difficult to apply compression or suspension to the urethra.

There is a lack of prospective randomised studies on the different anti-incontinence surgical procedures, and the AUS represents the standard by which other surgical treatments are compared (grade 2; level of recommendation B), even though technical problems related to the AUS are the long-term complications and expense.

Sling procedures are quicker and less invasive than implanting an AUS. In particular, the use of a transobturator approach seems to be safer and easier than the retropubic approach, with a lower incidence of intraoperative complications. At present there are long-term results only for the transobturator AdVance sling. The use of new transobturator sling models is still under clinical investigation and further clinical experience is needed to compare the transobturator approach with the retropubic approach.

## Conflict of interest

None.

## Source of Funding

None.

## References

- [1] Schroder A, Abrams P, Andersson KE. Guidelines on urinary incontinence. In: Arnheim AG, editor. *EAU guidelines*. Arnhem, The Netherlands: European Association of Urology; 2010. p. 11–28.
- [2] Shamliyan TA, Wyman JF, Ping R, Wilt TJ, Kane RL. Male urinary incontinence: prevalence, risk factors, and preventive interventions. *Rev Urol* 2009;**11**:145–65.
- [3] Berry JL. New procedure for correction of urinary incontinence. *J Urol* 1961;**85**:771–5.
- [4] Kaufman JJ. Urethral compression operations for the treatment of postprostatectomy incontinence. *J Urol* 1973;**110**:93–6.
- [5] Kishew SV. Suprapubic wad suspension. Combined perineal-abdominal approach for correction of postprostatectomy urinary incontinence. *Urology* 1978;**11**:28–32.
- [6] Kaufman JJ. Surgical treatment of post-prostatectomy incontinence: use of the penile crura to compress the bulbous urethra. *J Urol* 1972;**107**:293–7.
- [7] Clemens JQ, Bushman W, Schaeffer AJ. Questionnaire based results of the bulbourethral sling procedure. *J Urol* 1999;**162**:1972–6.
- [8] Rehder P, Gozzi C. Transobturator sling suspension for male urinary incontinence including post-radical prostatectomy. *Eur Urol* 2007;**52**:860–7.
- [9] Rehder P, Freiin von Gleissenthall G, Pichler R, Glodny B. The treatment of postprostatectomy incontinence with the retroluminal transobturator repositioning sling (Advance1): lessons learnt from accumulative experience. *Arch Esp Urol* 2009;**62**:860–70.
- [10] Rehder P, Mitterberger MJ, Pichler R, Kerschbaumer A, Glodny B. The 1 year outcome of the transobturator retroluminal repositioning sling in the treatment of male stress urinary incontinence. *BJU Int* 2010;**106**:1668–72.
- [11] Gozzi C, Becker AJ, Bauer R, Bastian PJ. Early results of transobturator sling suspension for male urinary incontinence following radical prostatectomy. *Eur Urol* 2008;**54**:960–1.
- [12] Bauer RM, Soljanik I, Fullhase C, Buchner A, May F, Steif CG, et al. Results of the AdVance transobturator male sling after radical prostatectomy and adjuvant radiotherapy. *Urology* 2011;**77**:474–9.
- [13] Cornel EB, Elzevier HW, Putter H. Can advance transobturator sling suspension cure male urinary postoperative stress incontinence? *J Urol* 2010;**183**:1459.
- [14] Gill BC, Swartz MA, Klein JB, Rackley RR, Montague DK, Vasavada SP, et al. Patient perceived effectiveness of a new male sling as treatment for post-prostatectomy incontinence. *J Urol* 2010;**183**:247–52.
- [15] Cornu JNS, Sebe P, Ciofu C, Peyrat L, Cussenot O, Haab F. Mid-term evaluation of the transobturator male sling for post-prostatectomy incontinence: focus on prognostic factors. *BJU Int* 2011;**108**:236–40.
- [16] Li H, Gill BC, Nowacki AS, Montague DK, Angermeier KW, Wood HM, et al. Therapeutic durability of male transobturator sling: midterm patient reported outcomes. *J Urol* 2012;**187**:1331–5.
- [17] Rehder P, Haab F, Cornu JN, Gozzi C, Bauer RM. Treatment of postprostatectomy male urinary incontinence with the transobturator retroluminal repositioning sling suspension: 3 year follow-up. *Eur Urol* 2012;**62**:140–5.
- [18] Bauer RM, Mayer ME, May F, Gratzke C, Buchner A, Soljanik I, et al. Complications of the AdVance transobturator male sling in the treatment of male stress urinary incontinence. *Urology* 2010;**75**:1494–8.
- [19] Serra AG, Folkersma LR, Dominguez-Escrig JL, Gomez-Ferrer L, Rubio-Briones L, Solsona Narbon E. AdVance/AdVance XP transobturator male slings: preoperative degree of incontinence as predictor of surgical outcome. *Urology* 2013;**81**:1034–9.

- [20] Davies TO, Bepple JL, McCammon KA. Urodynamic changes and initial results of the AdVance male sling. *Urology* 2009;**74**:354–7.
- [21] Bauer RM, Soljanik I, Fullhase C, Karl A, Becker A, Steif CG, et al. Mid-term results for the retroluminal transobturator sling suspension for stress urinary incontinence after prostatectomy. *BJU Int* 2011;**108**:94–8.
- [22] Grise P. Incontinence after prostatectomy, the transobturator male sling as a new treatment option. *Eur Renal Genito-Urinary Dis* 2006;**2**:69–70.
- [23] Grise P, Geraud M, Geraud M, Lienhart J, Le Portz B, Bubenheim M, et al. Transobturator male sling TOMS for the treatment of stress post-prostatectomy incontinence, initial experience and results with one year's experience. *Int Braz J Urol* 2009;**35**:706–15.
- [24] de Leval J, Waltregny D. The inside-out trans-obturator sling: a novel surgical technique for the treatment of male urinary incontinence. *Eur Urol* 2008;**54**:1051–65.
- [25] Leruth J, Waltregny D, de Leval J. The inside-out transobturator male sling for the surgical treatment of stress urinary incontinence after radical prostatectomy: midterm results of a single prospective study. *Eur Urol* 2012;**61**:608–15.
- [26] Romano S, Hübner W, Trigo Rocha F, Vaz F, Muller V, Nakamura F. The transobturator approach for treating postprostatectomy urinary incontinence with ARGUS T, the adjustable male sling. Early results of a multicenter trial. in: 24th EAU Congress. Stockholm, 2009. Available from: <http://www.promedon.com/recursos/argus/clinical-evidence-argus/2009/argust-dr.romanoetal-eau2009.pdf> Accessed August 2013.
- [27] Bauer W, Karik M, Schramek P. The self-anchoring transobturator male sling to treat stress urinary incontinence in men: a new sling, a surgical approach and anatomical findings in a cadaveric study. *BJU Int* 2005;**95**:1364–6.
- [28] Seweryn J, Bauer W, Ponholzer A, Schramek P. Initial experience and results with a new adjustable transobturator male system for the treatment of stress urinary incontinence. *J Urol* 2012;**187**:956–61.
- [29] Hoda MR, Primus G, Fischereder K, Von Heyden B, Mohammed N, Schmid N, et al. Early results of a European multicentre experience with a new self-anchoring adjustable transobturator system for treatment of stress urinary incontinence in men. *BJU Int* 2013;**111**:296–303.