

Acute Myocardial Infarction Following Blunt Chest Trauma-the Need for Third-Line Investigations in Medico-Legal Practice

S. R. Hulathduwa^{1*} and S. Raveendran²

¹*Department of Forensic Medicine, Faculty of Medical Sciences, University of Sri Jayawardenapura, Sri Lanka.*

²*Office of the JMO, Colombo South Teaching Hospital, Kalubowila, Sri Lanka.*

Authors' contributions

Both authors contributed equally in all aspects of this publication. Both authors read and approved the final manuscript.

Article Information

Editor(s):

(1) Dr. Arun Singh, Rohilkhand Medical College & Hospital, India.

Reviewers:

(1) Alexander Sosa Frias, The Cuban Hospital, Qatar.

(2) Abha Chandra, Sri Venkateswara Institute of Medical Sciences, India.

Complete Peer review History: <http://www.sdiarticle4.com/review-history/64520>

Case Report

Received 24 December 2020

Accepted 28 February 2021

Published 13 March 2021

ABSTRACT

Acute myocardial infarction is relatively uncommon among the young adults. Blunt trauma to chest is one rare mechanism of acute myocardial infarction specially among young adults. A 35-year-old male had sustained among other injuries, a blunt impact on the left side of his front chest and abdomen when his motor bike collided with a van from behind. ECG on admission to the accident and emergency unit showed ST segment elevations from V₂-V₆ together with elevated CPK and periodic changes of Troponin T. He was managed as for acute myocardial infarction. Streptokinase was not given due to high risk of bleeding following trauma. He had an uneventful recovery. Myocardial infarction could be precipitated by damage to coronary arteries due to non-penetrating blunt impact on the chest, the possible mechanisms being coronary artery dissection, intimal tears, sub-intimal hemorrhages, intra-luminal thrombosis and spasm. CT/MRI guided coronary angiography is considered the best investigation to exactly identify the aetiology. Blunt impact may also cause myocardial contusions which can also lead to an outcome similar to a myocardial infarction. The objective of this case report is to highlight that trauma and infarction (specially in a person with pre-existing ischaemia) will pose a wide array of medico-legal issues some of which are difficult to be answered by the clinician or the pathologist with certainty.

*Corresponding author: E-mail: sanjayarh@yahoo.co.uk;

Keywords: *Blunt chest trauma; traumatic myocardial infarction; commotio cordis; coronary angiography; traffic accidents.*

1. INTRODUCTION

Blunt cardiac injury remains a controversial topic in the field of trauma due to variations in terminology and the range of injuries and clinical presentations encompassed by the term [1]. This case report is aimed at elaborating such clinical complexities. Among non-atherosclerotic etiologies of acute myocardial infarction (MI) in young adults, blunt chest trauma is one of the rare mechanisms [2,3]. Blunt chest trauma may be due to road traffic accidents, sports activities including rugby, falls from significant heights and assaults specially stomping over the chest [4,5]. The possible mechanisms related to cardiac deaths following blunt chest injury are coronary artery dissection, intimal tears, sub-intimal hemorrhage, intra-luminal thrombosis and acute vasospasm [3]. Sudden cardiac death following trauma may also be due to cardiac concussion, commotio-cordis, contusio-cordis, cardiac rupture, valve and papillary muscle damage and catecholamine-induced events in a patient with atherosclerotic coronary artery disease [5].

2. CASE REPORT

A 35-year-old apparently healthy male without any significant past medical history, family history or coronary risk factors was admitted to the accident and emergency unit following a road traffic accident. The history revealed that he had collided with a van while riding his motor bike. The left side of his front chest and upper abdomen had sustained a blunt impact on the back of a moving van (and possibly also the handle of his own bike) when he was trying to overtake the van from behind. Subsequently, he fell on to his right side and sustained skeletal trauma on his right forearm and foot. He was aware of the incident and has developed chest pain within few minutes of the accident. On admission, he was in pain including that of the chest. Examination revealed diffuse tenderness and contusion on thoraco-abdominal region. His blood pressure was 120/70 mmHg. Other vital signs were within the physiological range and he did not have features of cardiac failure such as shortness of breath, tiredness, tachycardia or

rales of lung-bases, according to the clinical records.

The initial ECG showed right bundle branch block pattern and the repeated ECG revealed ST segment elevation in leads V₂ to V₆. (Fig. 1) Troponin T was 50 ng/ml after 12 hours of admission and five days later it was 18 ng/ml. CPK on the day of admission was 46 micro grams/l which has increased with time up to 104 micro grams/l and 197micro grams/l on the next two consecutive occasions. Other investigations were as follows: Prothrombin Time 14 s, control 13 s, Activated Partial Thromboplastin Time 35 s, International Normalized Ratio 1.1 and Thrombin Time 13s. Biochemical investigations for inflammatory markers were not done. The initial chest X-ray, CT scan of the brain and FAST scan (focused assessment with sonography in trauma) were all unremarkable. Pericardial effusion, haemopericardium, free fluid in the peri-hepatic and peri-splenic spaces in the abdomen, pneumothorax and haemothorax were not evident in the FAST scan. The initial antero-posterior chest X ray did not show any rib fractures, fracture dislocations of the costal cartilages and costo-chondral junction abnormalities. Further views of chest X rays and MRI or CT scans of the chest region were not employed. Other X-rays revealed fractures on the distal end of the right radius and ulna (Fig. 2), proximal phalanx of the third toe and base of the fifth metacarpal bone of the right foot. Echo cardiogram revealed hypokinesia in anterior, apical and septal areas of the heart. No valvular damages were detected and no evidence of cardiac failure was seen. A pericardial effusion was not evident echo-cardiographically. The pertinent investigation of CT/MRI guided coronary angiogram had not been performed. The follow-up lipid profile investigation was within the normal range. Streptokinase was not given due to the risk of bleeding following blunt trauma. He was treated with low molecular weight heparins (enoxaparin), clopidogrel, aspirin and statins. He was managed conservatively with bed rest and dietary modifications. Recovery was uneventful. The patient was discharged under the follow up of the cardiologist and the orthopedic surgeon.

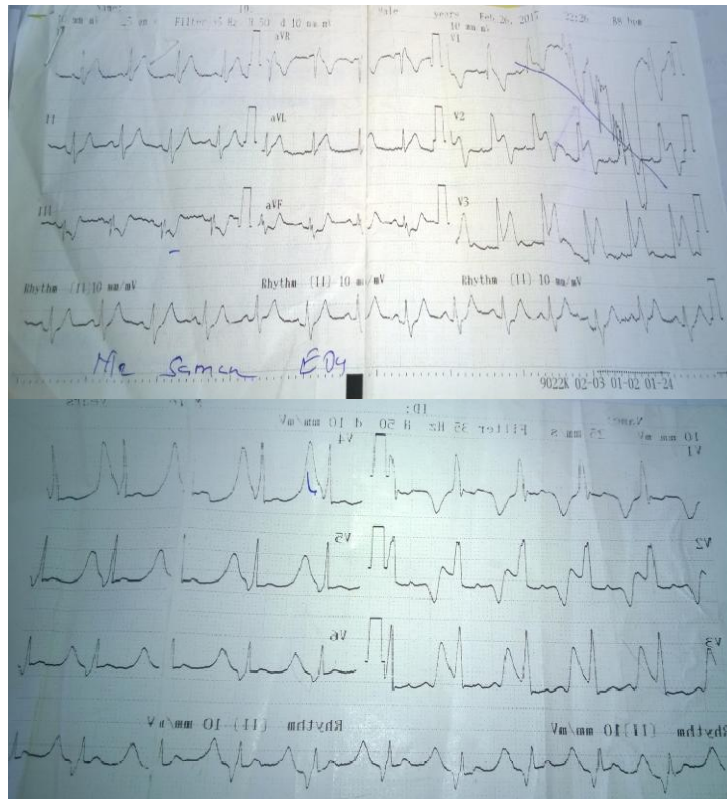


Fig. 1. ST segment elevations in antero-lateral leads

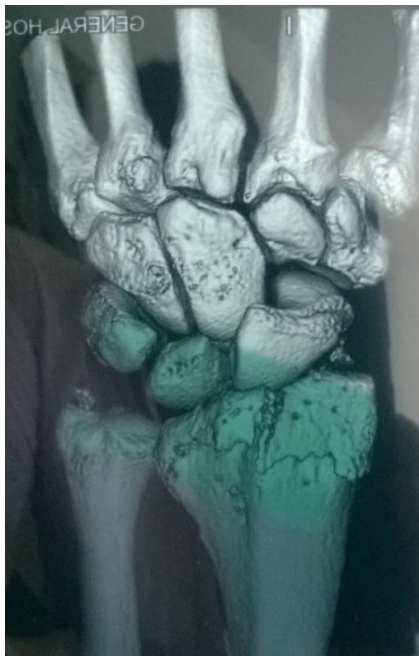

Fig. 2. Distal radial and ulna fractures

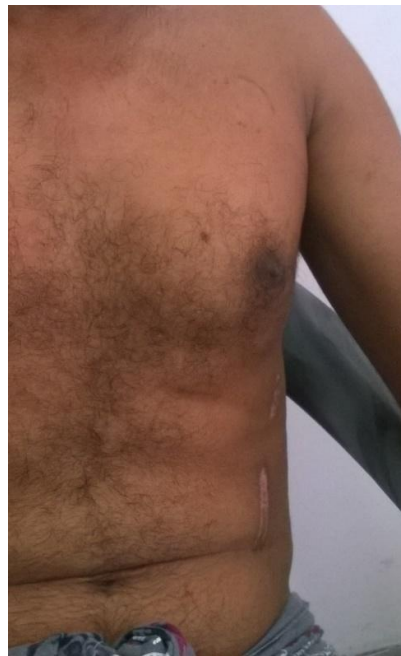

Fig. 3. Trauma to front of the chest and abdomen

3. DISCUSSION

Blunt cardiac injury (BCI) encompasses a spectrum of pathology ranging from clinically silent, transient arrhythmias (cardiac concussion, contusio-cordis) to myocardial infarction and cardiac wall rupture which may prove to be lethal [6,7]. Blunt cardiac trauma most commonly manifests as a myocardial contusion (contusio-cordis). These contusions can cause cardiac enzyme leaks, electrocardiographic abnormalities and cardiac contractile dysfunction making it difficult to differentiate from a peritraumatic myocardial infarction originating from natural occlusive coronary artery disease by atheroma [2]. Contused myocardium usually heals without any sequelae or residual injury. Rarely, it may undergo necrosis with rupture into pericardial sac perhaps several days after the injury to result in the formation of a haemopericardium [7] Myocardial infarction might be precipitated by damage to coronary arteries due to non-penetrating blunt chest trauma [3]. The possible mechanisms related to trauma and cardiac deaths are coronary artery dissection, intimal tear, sub-intimal hemorrhage, intraluminal thrombosis and spasm [3].

Sometimes, trauma can disturb the already existing atherosclerotic plaque (leading to rupture, ulceration and haemorrhage) and thereby trigger an acute coronary event [7,8]. Sudden cardiac events following trauma may also be due to coincidental occurrence of myocardial infarction before or after the accident in a subject with diagnosed or undiagnosed ischemic heart disease as well as due to catecholamine-induced vasospasm of coronary arteries with or without atherosclerotic coronary vessel disease [8]. Extreme psychological stress due to trauma may release catecholamines which may lead to pathological vasospasm. When vasospasm of arteriolar or arterial beds in the myocardium is of sufficient duration (20 to 30 minutes), a myocardial infarction may occur which is designated as cardiac Raynaud [8]. Elevated levels of catecholamines will further increase the heart rate and myocardial contractility, exacerbating the ischemic insult caused by the vasospasm [8].

This patient was admitted with chest pain and a cluster of blunt force injuries following road traffic trauma. The origin of the chest pain could have been due to one of the mechanisms described above. The other more plausible origin of the chest pain would also have been the contusion of

the chest wall which had also been documented on the Bed Head Ticket. However, it was difficult to locate a contusion on the aforesaid site, at the time of medico-legal examination which was conducted five days after the accident (Fig. 3). Patient himself claimed that the time interval between the onset of the chest pain and the trauma was only few minutes.

In this patient, the initial ECG showed right bundle branch block and repeated ECGs revealed ST elevations in leads V₂ to V₆. Troponin T was 50ng/ml and five days later it was 18ng/ml. These findings suggest myocardial damage or infarction by trauma and/or pre-existing undiagnosed ischemic heart disease. This was confirmed by Echo cardiogram findings which were compatible with the involvement of the left anterior descending artery depending on the segments of the heart which showed hypokinesia. This is the most vulnerable artery most frequently damaged following trauma [4,9]. Differentiation of traumatic from non-traumatic origin of myocardial infarction is very important both in the clinical point of view as well as in the medico-legal context though it is easily said than done for both the clinician as well as the forensic specialist. If myocardial infarction had been caused purely by trauma without pre-existing ischemic heart disease, then it may not need long term clinical follow up. In forensic point of view, it is important to decide whether the MI was caused by trauma or occlusive coronary artery disease as if it is of natural onset, categorization of hurt might not be changed. Furthermore, pre-existing ischaemia could be considered as a contributory factor in the causation of the RTA. It may act favorably for the driver of the offending vehicle.

If the myocardial infarction had been caused by trauma, it may have a significant impact upon the categorization of hurt, legal outcome, the liability of the offender and compensation. A charge of attempted murder may be formulated if attacked on the front of the chest with fist or with a blunt weapon expressing the intention or the knowledge of causing bodily injuries which are likely to cause death, when the episode ends up as a traumatically induced myocardial infarction.

In this case, the origin of the infarction cannot be decided with certainty because of the lack of tertiary investigations such as coronary angiogram (CT/MRI guided), other imaging techniques and myocardial biopsy [3]. CT/MRI guided coronary angiogram may diagnose and

differentiate natural occlusive coronary artery diseases caused by atheroma from coronary artery dissection, intimal tear, sub-intimal hemorrhage, intra-luminal thrombosis and spasm, all of which could be attributed to a traumatic event in the absence of pre-existing cardiac disease. Coronary angiogram had not been done in this case. The recent use of multi-detector CT scan (MDCT) with CT-angiography rapidly distinguishes myocardial contusion from peri-traumatic myocardial infarction and dictates as to which patients deserve extensive cardiac management [10]. Contrast-enhanced cardiac MRI is of assistance in differentiating cardiac contusions from acute peri-traumatic myocardial infarctions [11,12]. Pericardial injury, wall abnormalities and valvular abnormalities can also be detected in this technique. A severe contusion would be characterized by patchy and irregular myocyte necrosis associated with epicardial haemorrhage extending in pyramidal fashion intramurally or even trans-murally [13]. In mild cases red blood cells could be seen between the intact myocytes. Endo myocardial biopsy may detect myocardial contusions. It is also helpful in histological dating of cardiac injuries though endo-myocardial biopsy might not have been clinically indicated in this case. Though this approach could guide medico-legal management, it is rarely performed solely for the purpose of managing medico-legal issues. Even though it is highly suggestive in this case that the origin of the MI was post-traumatic, it cannot be categorically proved in the inadequacy of tertiary-level investigations.

When the overall clinical management of this patient under the care of the cardiologist, which involved subjecting him to a wide array of cardiological investigations, administration of infusions of low molecular weight heparins and repeated monitoring is considered, the category of hurt may reasonably be opined as fatal in the ordinary cause of nature. At the same time, this case fails to demonstrate the mechanism confidently as discussed above. Therefore, the hurt was categorized as grievous focusing only on the remaining injuries.

4. CONCLUSION

Atherosclerotic origin of the MI could not be ruled out completely in this case as angiography had not been performed. Yet, there is a very high possibility that the acute coronary event in this person was triggered following blunt trauma to chest. Proving non-atherosclerotic origin of the

MI has a therapeutic value in the long term follow-up as well as a medico-legal value when forensic issues such as category of hurt and compensation are considered. Differentiation of these injuries in relation to penetrating and non-penetrating trauma warrants tertiary level investigations to prove the culpability beyond reasonable doubt in courts of law. At present, such high-cost investigations are not routinely performed even for treatment purposes in government hospitals especially in low and middle income countries including Sri Lanka, if patients are hemodynamically stable.

CONSENT

Written informed consent of the patient had been obtained for publishing the details including the photograph though the photograph does not lead to the direct identification.

ETHICAL APPROVAL

As per international standard or university standard written ethical approval has been collected and preserved by the author(s).

COMPETING INTERESTS

Authors have declared that no competing interests exist.

REFERENCES

1. Brewer B, Zarzaur B. Cardiac contusions. *Current Trauma Reports*. 2015;1(4):232-236.
2. Southam S, Jutila C, Ketai L. Contrast-enhanced Cardiac MRI in Blunt Chest Trauma: Differentiating Cardiac Contusion from Acute Peri-traumatic Myocardial Infarction. *Journal of Thoracic Imaging*. 2006;21(2):176-178.
3. Patil R, Mane D, Jariwala P. Acute myocardial infarction following blunt chest trauma with intracranial bleed: A rare case report. *Indian Heart Journal*. 2013;65(3): 311-314.
4. Saukko P, Knight B. *Knight's Forensic Pathology Fourth Edition*. 4th ed. Boca Raton: Chapman and Hall/CRC; 2015.
5. Marcolini E, Keegan J. Blunt cardiac injury. *Emergency Medicine Clinics of North America*. 2015;33(3):519-527.
6. Spitz WU. Road traffic victim. In: Spitz and Fisher's *Medico legal investigation of death*. 4th Ed. U.S.A: Charles C Thomas Publishers Ltd. 2005;903-965.

7. DiMaio V. Forensic Pathology. 2nd ed. Hoboken: CRC Press; 2001.
8. Richard NM. Blood vessels. In: Robbins and Cotran Pathologic basis of disease. 1st ed. India: Thomson Press Ltd. 2015;483-22.
9. Spitz WU. Blunt force injury. In: Spitz and fisher's medico legal investigation of death. 4th ed. U.S.A: Charles C Thomas Publishers Ltd. 2005;460-531.
10. Co S, Yong-Hing C, Galea-Soler S, Ruzsics B, Schoepf U, Ajlan A, et al. Role of imaging in penetrating and blunt traumatic injury to the heart. Radio Graphics. 2011;31(4):E101-E115.
11. Malbranche G, Serfaty J, Himbert D, Steg P, Laissy J. Myocardial infarction after blunt chest trauma: Usefulness of cardiac ECG-gated CT and MRI for positive and aetiologic diagnosis. Emergency Radiology. 2011;18(3):271-274.
12. Southam S, Jutila C, Ketai L. Contrast-enhanced cardiac MRI in blunt chest trauma: Differentiating cardiac contusion from acute peri-traumatic myocardial infarction. Journal of Thoracic Imaging. 2006;21(2):176-178.
13. Kaye P. Myocardial contusion: Emergency investigation and diagnosis. Emergency Medicine Journal. 2002;19(1):8-10.

© 2021 Hulathduwa and Raveendran; This is an Open Access article distributed under the terms of the Creative Commons Attribution License (<http://creativecommons.org/licenses/by/4.0>), which permits unrestricted use, distribution, and reproduction in any medium, provided the original work is properly cited.

Peer-review history:

*The peer review history for this paper can be accessed here:
<http://www.sdiarticle4.com/review-history/64520>*