



# Minocycline Induced Ossicular Chain Pigmentation

Roya Azadarmaki<sup>1\*</sup> and Sanjay Prasad<sup>1</sup>

<sup>1</sup>Metropolitan Neuro Ear Group, 1101 Wootton Parkway Suite 900, Rockville, MD 20852, USA.

## Authors' contributions

This work was carried out in collaboration between both authors. Authors RA and SP wrote the first draft of the manuscript, managed the literature searches and finalized the manuscript. Both authors read and approved the final manuscript.

## Article Information

DOI: 10.9734/BJMMR/2016/22166

### Editor(s):

(1) S. U. Fuhong, ICU Laboratory, Erasme Hospital, Free University Brussels, Brussels, Belgium.

### Reviewers:

- (1) Haruki Komatsu, Toho University, Japan.  
(2) Kowichi Jimbow, Sapporo Medical University, Japan.  
(3) Manu Sehrawat, Post Graduate Institute of Medical Education and Research, India.  
Complete Peer review History: <http://sciencedomain.org/review-history/12504>

## Case Report

Received 21<sup>st</sup> September 2015  
Accepted 17<sup>th</sup> November 2015  
Published 2<sup>nd</sup> December 2015

## ABSTRACT

Pigmentation is a well-recognized complication of minocycline use. This is the first reported case of ossicular chain pigmentation as a consequence of this drug. Isolated pigmentation of the lenticular process of the incus bone was noted. The structural integrity and function of the ossicular chain was not influenced by these changes.

**Keywords:** Minocycline; bone pigmentation; ossicular chain; incus.

## 1. INTRODUCTION

Pigmentation is a well-recognized complication of minocycline use [1]. Skin is the most common site of pigmentation [1]. Pigmentation of the teeth, nails, thyroid gland, mucus membranes, bones, cartilage, breast milk, heart valves, atherosclerotic plaques, sclera, and conjunctiva

has been reported [1]. The authors report the first case in the literature of ossicular chain pigmentation with minocycline use. An Institutional Review Board Exemption was obtained from the George Washington University Office of Human Research prior to submission of this report.

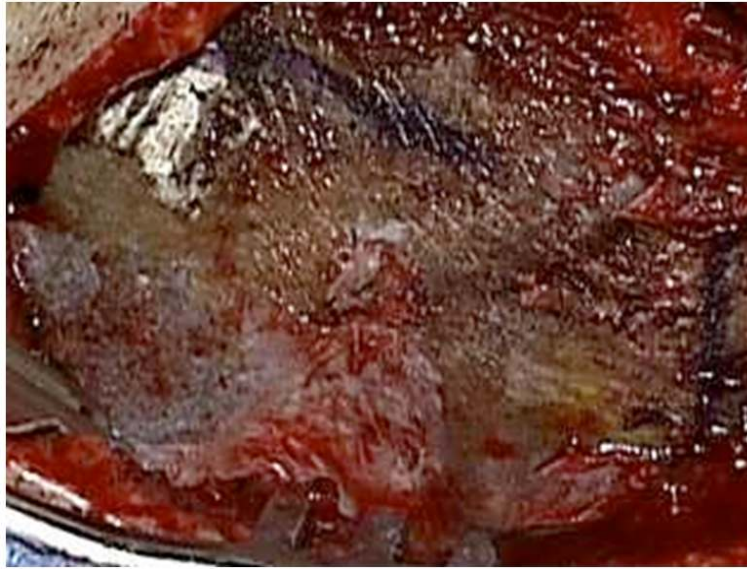\*Corresponding author: E-mail: [razadarm@temple.edu](mailto:razadarm@temple.edu);

## 2. CASE REPORT

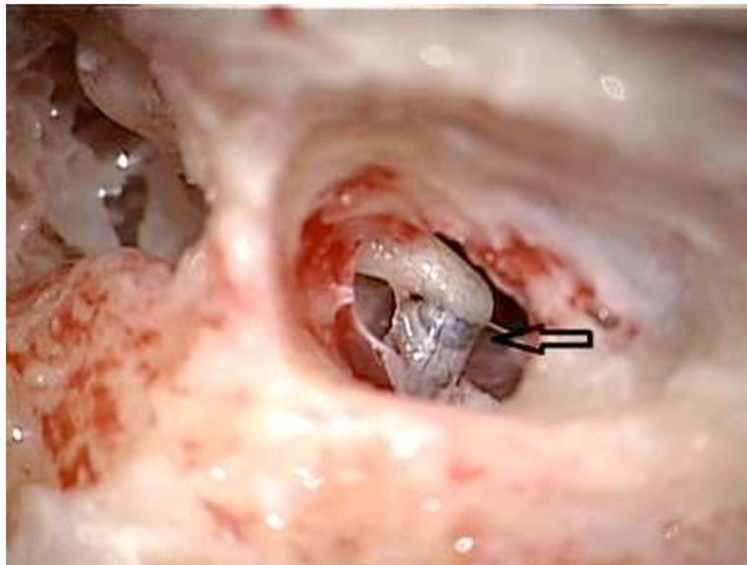
A 40-year-old woman with a history of prolonged minocycline use for acne (80 mg/day for at least 25 years) and bilateral sensorineural hearing loss underwent a right mastoidectomy and extended facial recess approach for insertion of a totally implantable hearing device. Intraoperatively, pigmentation of the outer cortex of the parietal and temporal bones were noted (Fig. 1). Bone

integrity was normal. Other than minocycline, the patient was not on any medications or herbal remedies associated with bone pigmentation.

The encountered pigmentation faded away with drilling from the mastoid cortex medially towards the antrum and middle ear structures; however, isolated pigmentation of the lenticular process of the incus was observed (Figs. 2 and 3).



**Fig. 1. Pigmented outer cortex of the parietal and temporal bones**



**Fig. 2. The incudostapedial joint is seen through the facial recess. Arrow is pointing to the pigmented lenticular process of the incus bone**



**Fig. 3. The needle is pointing to the pigmented lenticular process of the incus bone. The discoloration on the other end is an artifact of laser resection**

The ossicular chain was mobile with no other noted architectural or functional deficits. The middle ear implant was successfully placed surgically with no variations from normal protocol.

Review of preoperative computed tomography and magnetic resonance imaging revealed no bony abnormalities. Patient was advised to stop the use of minocycline and to consult her dermatologist to discuss alternative options for acne treatment.

### **3. DISCUSSION**

Pigmentation as a sequela of minocycline is a known complication [1]. Of all the tetracyclines, minocycline is most commonly associated with this complication. Skin is the most common site of pigmentation [1]. Skin pigmentation can be reversible over the course of several months to years with discontinuation of minocycline [1]. Oral cavity structures such as the alveolar bone, and less commonly the oral mucosa and teeth are other sub-sites that can undergo pigmentation [1]. Pigmentation of peri-articular bone as an incidental finding in joint replacement surgery has also been reported in the orthopedic literature [2,3,4]. The peri-articular nature of the

pigmentation parallels our intraoperative findings of pigmentation along the incudostapedial joint at the level of the lenticular process of the incus.

Involvement of bone and cartilage is less common and may not be reversible [1]. The incidence of intraoral bone pigmentation at a dose of 100-200mg/day is 10% after 1 year of therapy and increases to 20% after 4 years [1]. Involvement of the calvarium and craniofacial skeleton beyond the oral cavity alveolar bone has rarely been reported [5,6]. In 1976 Attwood and Dennett reported discoloration of the parietal bones and nasal ala on autopsy of a patient treated with minocycline for one year [5]. Laure et al. encountered black pigmentation of the entire craniofacial skeleton exposed through a coronal approach in an individual treated with 200 mg/day of minocycline for 3 years [6]. In 2015 Farahnik et al. [7] also reported a rusty green discoloration of the temporal bone in a patient with a 5 year history of minocycline use undergoing a tympanomastoidectomy.

Deposition of minocycline's black degradation product or a drug complex in tissue may, in part, explain the pigmentation that results with its use [8]. The deposit contains iron and calcium and resembles hemosiderin [8]. The effect on bone

metabolism is unknown however the structure and function of bone seems to be unaffected [9]. The pigmentation in bone is probably irreversible as insoluble salts are deposited in bone [1]. The intensity of pigmentation may decrease over several years with discontinuation of the drug [1].

This is the first report of ossicular chain pigmentation in the literature secondary to minocycline use. The pigmentation of the ossicular chain in this patient had no impact on her ossicular chain function and structural integrity. There is no evidence that bony pigmentation secondary to minocycline use affects the structure and function of bone in all cases reported, however discontinuation of minocycline remains the universal recommendation. The absence of functional abnormalities suggests that surgical intervention may continue when such discoloration is noted.

#### 4. CONCLUSION

Ossicular chain pigmentation can occur as a consequence of prolonged Minocycline use. The structural integrity and function of bone is not influenced by these changes.

#### CONSENT

It is not applicable.

#### ETHICAL APPROVAL

An Institutional Review Board Exemption was obtained from the George Washington University Office of Human Research prior to submission of this report.

#### COMPETING INTERESTS

Authors have declared that no competing interests exist.

#### REFERENCES

1. Eisen D, Hakim M. Minocycline-induced pigmentation, incidence, prevention and management. *Drug Safety*. 1998;18(6): 431-440.
2. Yang S, Takakubo Y, Kobayashi S, Asano T, Sasaki A, Sasaki K, Ohki H, Tamaki Y, Takagi M. Minocycline-induced periarticular black bones in inflamed joints which underwent arthroplastic reconstruction. *Clin Orthop Surg*. 2012;4(3):181-7.
3. Reed DN, Gregg FO, Corpe RS. Minocycline-induced black bone disease encountered during total knee arthroplasty. *Orthopedics*. 2012;35(5):e737-9.
4. Chauhan V, McDougall C. Black bones: Minocycline-induced bone pigmentation. *Med J Aus*. 2014;201(2):114.
5. Attwood H, Dennett X. A black thyroid and minocycline treatment. *Br Med J*. 1976;2: 1109-10.
6. Laure B, Petraud A, Sury F, Bayol JC, Marquet-Van Der Mee N, dePinieux G, Goga D. Black bone disease of the skull and facial bones. *Rev Stomatol Chir Maxillofac*. 2009;110(5):303-5.
7. Farahnik B, Zaghi S, Hendizadeh L, Gopen Q. Rusty green stained temporal bone associated with exposure to tetracycline: An unusual presentation of blackbone disease. *J Laryngol Otol*. 2015;129(3): 276-8.
8. Rumbak MJ, Pitcock JA, Palmieri GM, Robertson JT. Black bones following long-term minocycline treatment. *Arch Pathol Lab Med*. 1991;115:939-41.
9. Okland S, Prolo DJ. The significance of yellow bone. *JAMA*. 1981;246:761-3.

© 2016 Azadarmaki and Prasad; This is an Open Access article distributed under the terms of the Creative Commons Attribution License (<http://creativecommons.org/licenses/by/4.0>), which permits unrestricted use, distribution, and reproduction in any medium, provided the original work is properly cited.

*Peer-review history:*  
*The peer review history for this paper can be accessed here:*  
<http://sciencedomain.org/review-history/12504>