



---

## **Occurrence of Cubital Tunnel Syndrome Due to a Synovial Cyst: A Case Report**

**Rami Ben Arab<sup>1\*</sup>, Khaled Khelil<sup>1</sup>, Amira Gallas<sup>1</sup>, Leila Essid<sup>1</sup>, Khaled Bchir<sup>2</sup>,  
Riadh Maalla<sup>3</sup> and Mohamed Ali Sbai<sup>1</sup>**

<sup>1</sup>*Department of Orthopaedic and Trauma Surgery, Mohamed Taher Al Maamouri Hospital, Nabeul, Tunisia.*

<sup>2</sup>*Department of Legal Medicine, Mohamed Taher Al Maamouri Hospital, Nabeul, Tunisia.*

<sup>3</sup>*Department of Plastic Surgery, Rabta Hospital, Tunis, Tunisia.*

### **Authors' contributions**

*This work was carried out in collaboration among all authors. Author RBA designed the study, performed the statistical analysis, wrote the protocol and wrote the first draft of the manuscript. Authors MAS and KB managed the analyses of the study. Author KK managed the literature searches. All authors read and approved the final manuscript.*

### **Article Information**

#### Editor(s):

(1) Dr. Wagih Mommtaz Ghannam, Professor, Department of General Surgery, Faculty of Medicine, Mansoura University, Egypt.

#### Reviewers:

(1) Elham Loni, University of Social Welfare and Rehabilitation Sciences, Iran.

(2) Vinay Jagga, Prem Physiotherapy and Rehabilitation College, India.

Complete Peer review History: <http://www.sdiarticle3.com/review-history/51064>

**Case Study**

**Received 25 June 2019**  
**Accepted 31 August 2019**  
**Published 07 September 2019**

---

### **ABSTRACT**

The cubital tunnel syndrome is a compressive neuropathy of the ulnar nerve around the elbow. It is the most common neurocompression syndrome in the upper limb after carpal tunnel syndrome. Ulnar nerve entrapment is usually located under the thickening of the proximal fascia between two heads of the ulnar flexor of the carpus, or in the arcade of Osborne at the distal part of the epicondylar curve. However, it can also be caused by occupying masses along the course of the nerve.

This report shows a case of cubital tunnel syndrome caused by ulnar entrapment by a medial synovial cyst. Epidemiology, pathogenesis and diagnosis were discussed and literature was reviewed.

**Keywords:** Ulnar nerve; nerve compression; cubital tunnel syndrome; ulnar nerve release; synovial cyst.

## 1. INTRODUCTION

Cubital tunnel syndrome is asymptomatic ulnar nerve dysfunction at the level of the elbow resulting from a combination of compression, traction, and friction. It is one of the most prevalent upper extremity compressive neuropathies. It is the second most common nerve compression syndrome in peripheral nerve compression disease [1]. However, potential ulnar nerve entrapment can occur in multiple points along its course, such as the arcade of Struthers, the medial intermuscular septum, the medial epicondyle, the cubital tunnel and the deep flexor-pronator aponeurosis. The most common site of entrapment is the cubital tunnel and has been referred to as the tardy ulnar nerve palsy in the past [2,3].

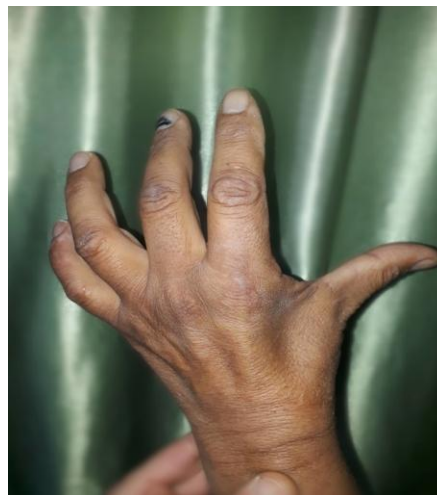However, ulnar nerve entrapment can also be caused by the occupying masses along the course of ulnar nerve. We present a rare case of cubital tunnel syndrome caused by a synovial cyst. This work aims to study the different epidemiological, etiopathogenic, clinical presentation and treatment of this rare disease. A literature review was made.

## 2. CASE REPORT


A 58-year-old man who has been suffering from progressive paraesthesia on the left upper extremity visited our hospital. A tingling sensation on medial two fingers and the ulnar side of the limb developed a year ago. There was no history

of previous trauma at the left elbow, neither a history of diabetes nor vascular, nor neuropathic diseases. On direct questioning he reported a worsening of the tingling and the loss of strength 6 months ago. Clinically he had atrophy of the hypothenar and interosseous muscle in the left hand. Froment's sign was positive. Tinel's sign was also positive at the medial side of the elbow. Sensory examination revealed loss of normal discrimination on the entire little finger and the ulnar side of the ring finger. Elbow radiographs did not show degenerative changes nor proliferative osteophyte nor calcific disposition. The nerve conduction studied with electromyography revealed evidence of ulnar nerve compression at the elbow. Ultrasonography revealed a cystic mass that compressed the ulnar nerve which at the level of cubital tunnel.

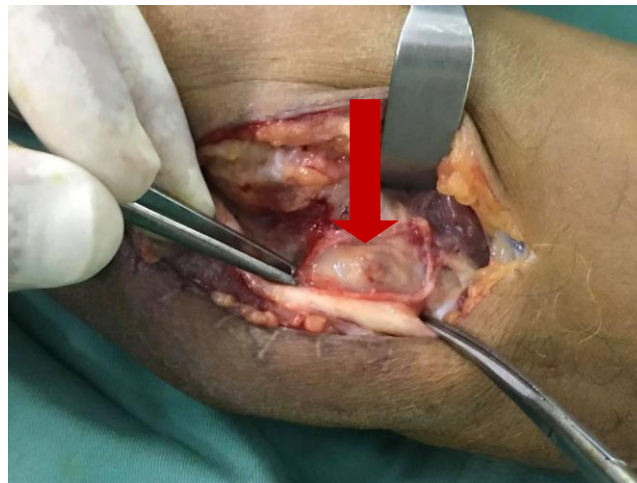To relieve the nerve compression, surgery was planned. After induction of general anaesthesia, interior sweeping 10 cm incision around medial epicondyle was made. The subcutaneous tissues were dissected, identifying the ulnar nerve who was flattened and compressed in the cubital tunnel by a synovial cyst the diameter of which was 2 cm. we resected the cyst completely. After further exploration, we did not find another point of compression. The arcade of Struthers, Osborne's fascia and the deep flexor-pronator aponeurosis were divided. Then, an anterior subcutaneous transposition of the nerve was performed to avoid re-compression by the cyst recurrence. Synovial cyst was confirmed by histopathological examination.



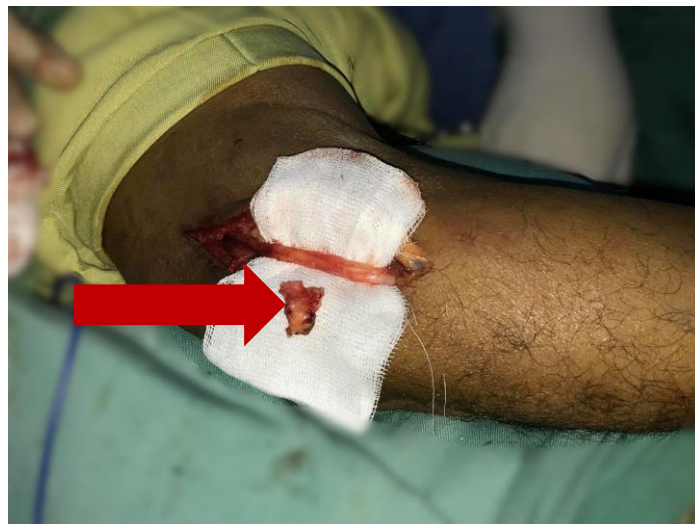**Fig. 1. Clinical photograph demonstrating a claw hand deformity and intrinsic muscle atrophy**



**Fig. 2. Preoperative ultrasonography shows ulnar nerve compressed by anechoic mass**



**Fig. 3. Intraoperative photograph showing the cyst compressing the ulnar nerve in the cubital tunnel**



**Fig. 4. Intraoperative photograph showing total removal of the cyst**

### 3. DISCUSSION

Cubital tunnel syndrome is a common and debilitating condition that can be overlooked until nerve damage has occurred [4].

Diagnosis of cubital tunnel syndrome is made through a combination of history, physical examination, and an electroneurographic examination.

Paresthesia is anticipated in the little finger and ulnar half of the ring finger. The weakness of the interossei, the adductor pollicis, and the ulnar lumbrical muscles, which occurs with advanced disease, may cause characteristic posturing in the hand (Wartenberg sign, Froment sign, and claw hand deformity, respectively) [5,6].

Cubital tunnel syndrome may be categorized as mild, moderate, or severe disease. Common grading systems include modified McGowan and Dellon classifications [1].

The use of imaging, such as sonography and MRI, to detect the cause of compressions, including substantial or cystic mass that are rare and unexpected [2,7,8].

The ulnar nerve may be compressed at multiple points along its course, the most common location is at the elbow [9].

There are 4 sites where the ulnar nerve is frequently vulnerable to compression. These are (1) the arcade of Struthers (medial intermuscular septum), (2) the ulnar groove, (3) the humeroulnar arcade (or cubital tunnel), and (4) the exit point between the two heads of FCU. Among these locations, the most common sites of compression are the ulnar groove and humeroulnar arcade [4].

Cubital tunnel syndrome can be caused by soft-tissue masses such as ganglia [10] synovial chondromatosis [11] which might compress the ulnar nerve as it lies in the condylar groove or within the cubital tunnel.

In previous reports, synovial cysts were related to the post-traumatic osteoarthritis of the elbow and can cause a relatively acute onset of cubital tunnel syndrome [11].

The elbow cyst with cubital tunnel syndrome is rarely reported in the literature. The prevalence rate is 3~8% [2], and there have been

occasional case reports in Europe and the United States [12].

Kato [10] thought that the morbidity rate of the disease is up to 8% in a large sample of 472 patients. Which is comparable to results found in Tong's study who reported a 4% prevalence [13].

Conservative treatment measures focus on pain relief, inflammation reduction, and rehabilitation. This includes patient education and behaviour modification, non-steroidal anti-inflammatories, night splints, elbow pads, physical therapy, ultrasound, pulsed signal therapy, and corticosteroid injections.

If conservative management is not successful in preventing progression of impairment after several months, surgery may be required.

There are still debates on which surgical procedure is optimal for the treatment of cubital tunnel syndrome [13]. Some authors favour anterior transposition [14], whereas others report high success rates with simple decompression [15] or medial epicondylectomy [16].

For the treatment, though in situ decompression was considered as a good choice in recent years, the decompression with subcutaneous transposition was a better procedure for avoiding re-compression caused by the cyst recurrence after the cysts were removed [17,18].

### 4. CONCLUSION

Cubital tunnel syndrome is a common condition that can be overlooked until after nerve damage occurs. Timely recognition and treatment is paramount to good clinical outcomes to avoid irreversible muscle atrophy and functional deficit. In our case, a rarely etiology, a synovial cyst, caused the compression. This soft-tissue mass was susceptible to be missed and ignored during the treatment using in situ decompression with the mini-incision. The regular incision is beneficial for finding some little mass to avoid the second operation for the incomplete release or recurrent symptomatology. In our opinion, decompressing the nerve with subcutaneous transposition was a good procedure for avoiding recompression caused by an eventual cyst recurrence.

### CONSENT AND ETHICAL APPROVAL

As per university standard guideline participant consent and ethical approval has been collected and preserved by the authors.

## COMPETING INTERESTS

Authors have declared that no competing interests exist.

## REFERENCES

1. Boone S, Gelberman RH, Calfee RP. The management of cubital tunnel syndrome. *J Hand Surg Am.* 2015;40(9):1897-904.
2. Chang WK, Li YP, Zhang DF, Liang BS. The cubital tunnel syndrome caused by the intraneural or extraneural ganglion cysts: Case report and review of the literature. *J Plast Reconstr Aesthet Surg.* 2017;70(10):1404-1408.
3. Wojewnik B, Bindra R. Cubital tunnel syndrome - Review of current literature on causes, diagnosis and treatment. *J Hand Microsurg.* 2009;1(2):76-81.
4. Robertson C, Saratsiotis J. A review of compressive ulnar neuropathy at the elbow. *J Manipulative Physiol Ther.* 2005;28(5):345.
5. Root CG, London DA, Schroeder NS, Calfee RP. Anatomical relationships and branching patterns of the dorsal cutaneous branch of the ulnar nerve. *J Hand Surg Am.* 2013;38(6):1131-6.
6. Andrews K, Rowland A, Pranjali A, Ebraheim N. Cubital tunnel syndrome: Anatomy, clinical presentation, and management. *J Orthop.* 2018;15(3):832-836.
7. Gregoli B, Bortolotto C, Draghi F. Elbow nerves: Normal sonographic anatomy and identification of the structures potentially associated with nerve compression. A short pictorial-video article. *J Ultrasound.* 2013;16(3):119-21.
8. Chiou HJ, Chou YH, Cheng SP, Hsu CC, Chan RC, Tiu CM, Teng MM, Chang CY. Cubital tunnel syndrome: diagnosis by high-resolution ultrasonography. *J Ultrasound Med.* 1998;17(10):643-8.
9. Karatas A, Apaydin N, Uz A, Tubbs R, Loukas M, Gezen F. Regional anatomic structures of the elbow that may potentially compress the ulnar nerve. *J Shoulder Elbow Surg.* 2009;18(4):627-31.
10. Kato H, Hirayama T, Minami A, Iwasaki N, Hirachi K. Cubital tunnel syndrome associated with medial elbow Ganglia and osteoarthritis of the elbow. *J Bone Joint Surg Am.* 2002;84(8):1413-9.
11. Kim CH, Kim SH, Kim MS, Chang CH. Cubital tunnel syndrome, associated with synovial chondromatosis. *J Korean Neurosurg Soc.* 2008;43(2):109-10.
12. Palmer BA, Hughes TB. Cubital tunnel syndrome. *J Hand Surg Am.* 2010;35(1):153-63.
13. Tong J, Xu B, Dong Z, Liu J, Zhang C, Gu Y. Cubital tunnel syndrome caused by ganglion cysts: A review of 59 cases. *Acta Neurochir (Wien).* 2017;159(7):1265-1271.
14. Kleinman WB. Cubital tunnel syndrome: anterior transposition as a logical approach to complete nerve decompression. *J Hand Surg Am.* 1999;24(5):886-97.
15. Pavelka M, Rhombert M, Estermann D, Löscher WN, Piza-Katzer H. Decompression without anterior transposition: An effective minimally invasive technique for cubital tunnel syndrome. *Minim Invasive Neurosurg.* 2004;47(2):119-23.
16. Muermans S, De Smet L. Partial medial epicondylectomy for cubital tunnel syndrome: Outcome and complications. *J Shoulder Elbow Surg.* 2002;11(3):248-52.
17. Grandizio LC, Maschke S, Evans PJ. The management of persistent and recurrent cubital tunnel syndrome. *J Hand Surg Am.* 2018;43(10):933-940.
18. Li Y, Lao J. The cubital tunnel syndrome caused by the two synovial cysts. *J Plast Reconstr Aesthet Surg.* 2012;65(6):827-9.

© 2019 Arab et al.; This is an Open Access article distributed under the terms of the Creative Commons Attribution License (<http://creativecommons.org/licenses/by/4.0>), which permits unrestricted use, distribution, and reproduction in any medium, provided the original work is properly cited.

Peer-review history:

The peer review history for this paper can be accessed here:  
<http://www.sdiarticle3.com/review-history/51064>