

## **Oncogenic Osteomalacia Secondary to Hemangiopericytoma - A Case Report**

**Gajanan Deshmukh <sup>a\*</sup> and Uday Phute <sup>a</sup>**

<sup>a</sup> *Seth Nandlal Dhoot Hospital Aurangabad, India.*

### **Authors' contributions**

*This work was carried out in collaboration between both authors. Both authors read and approved the final manuscript.*

### **Article Information**

#### Editor(s):

(1) Dr. Parth Trivedi, C.M. Patel College of Physiotherapy, Civil Hospital Campus, India.

#### Reviewers:

(1) Afaf Taha Ibrahim, Northern Border University, Saudi Arabia.

(2) Igna Cornel, University of Agricultural Science and Veterinary Medicine of Banat, Romania.

Complete Peer review History, details of the editor(s), Reviewers and additional Reviewers are available here:

<https://www.sdiarticle5.com/review-history/76893>

**Case study**

**Received 30 September 2021**

**Accepted 01 December 2021**

**Published 07 December 2021**

### **ABSTRACT**

One of the rare paraneoplastic syndrome of osteomalacia is oncogenic osteomalacia or tumor induced osteomalacia (TIO) where there is phosphate depletion and abnormal vitamin metabolism caused due to small endocrine tumor that secretes phosphaturic hormone, fibroblast growth factor [1]. Phosphaturic mesenchymal tumour is very uncommon and is very difficult to diagnose. Usually it is misdiagnosed as other mesenchymal tumour due to its heterogeneity [1]. There is inappropriate FGF-23 secretion which causes low phosphate and 1,25-dihydroxyvitamin D levels [2,3].

We are going to present a case of hypophosphatemic rickets secondary to phosphaturic mesenchymal tumour who came with complaints of proximal muscle weakness which limited his effort tolerance and activities of daily life like standing from squatting position and rib pain. His FGF-23 levels were very high above normal levels and PET CT revealed a well-defined enhancing lesion abutting femoral neurovascular bundle. After consultation with endocrinologist we have done complete excision of the mass. Post surgery all symptoms were relieved, proximal muscle strength improved gradually and serum levels of phosphorus, ALP and FGF-23 came back to normal.

**Keywords:** *Fibroblast growth factor-23; phosphaturic mesenchymal tumour; oncogenic osteomalacia.*

## 1. INTRODUCTION

Osteomalacia (mollities ossium) is a metabolic bone disease which results from inadequate mineralisation of osteoid in mature bone in adults. Osteomalacia is a rare inborn error of metabolism. Oncogenic osteomalacia (OO) is a rare type of osteomalacia in which there is systemic demineralisation of bone. Common Symptoms of OO are bony pain, muscle wasting and fractures [3]. Metabolically there will be renal phosphate wasting, hypophosphatemia, decreased serum-1,25 dihydroxyvitamin levels and resistance to vitamin D supplementation.

TIO like syndrome can also be associated with some other diseases like prostate cancer, hematologic malignancies, neurofibromatosis, epidermal nevus syndrome, and polyostotic fibrous dysplasia of bone [4,5,6]. This disease was first described by Dr. Rober McCane ,he observed patient presenting with pain, weakness and abnormal gait with low phosphate levels. He tried to treat patient with high dose of vitamin D but did not succeed. The symptoms were cured by resection of tumor.

OO had association with syndromes such as neurofibromatosis and McCune-Albright syndrome and in patient with carcinomas. It has been reported that OO associated with mesenchymal tumour over expresses FGF-23. This protein inhibits renal tubular epithelial phosphate transport and this is thought to be the mechanism for most cases of OO.

Weidner and Santa Cruz (1987) coined the term "Phosphaturic Mesenchymal Tumour, Mixed Connective Tissue variant" (PMTMCT). Histologically PMTMCT us a mixture of spindle

cells, osteoclast like giant cells, prominent blood vessels, cartilage like Matrix and metaplastic bone.

## 2. CASE REPORT

A 38 yrs old male presented to neurophysician with complaint of difficulty in walking, weakness in bilateral lower limb left more than right with waddling gait and pain in ribs. All the symptoms were insidious in onset, gradually progressive limiting his daily routine activities. Patient also complained of difficulty in standing from squatting position and breathlessness after waking for 50-100 meters. Nerve conduction study was within normal limits. Laboratory parameters were Sr.Calcium- 9.47mg/dl, Sr.Phosphorus -1.48 IU/L, Alkaline Phosphatase-175.3 IU/L. Patient was treated symptomatically with phosphorus supplements but he was not relived rather his symptoms progressed. Patient was then referred to us. On further evaluation we have noticed Sr.Phosphorus – 1.46 mg % (value) and 1,25-dihydroxyvitamin value- 14.08 ng/ml and was diagnosed to have osteomalacia . X ray femur showed losers zone so patient was primarily diagnosed as hypophosphatemic rickets and started on oral calcium and vit D supplements. Symptoms of patient increased in intensity even after the treatment which pinned towards an endocrine pathology.

Endocrinologist's opinion was taken who suggested to get FGF-23 level checked. FGF-23 levels came out to be very high 1117.6 RU/ml(Normal value:-0-150RU/ml).

PET scan was done which further revealed well defined enhancing lesion involving medial compartment of left upper thigh abutting femoral vein suggestive of Hemangiopericytoma.

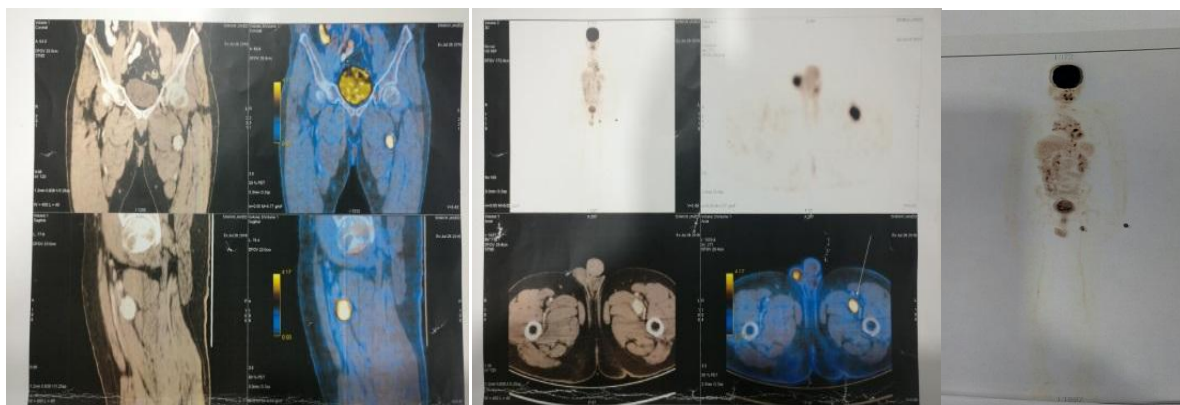

Fig. 1. PET scan of lesion

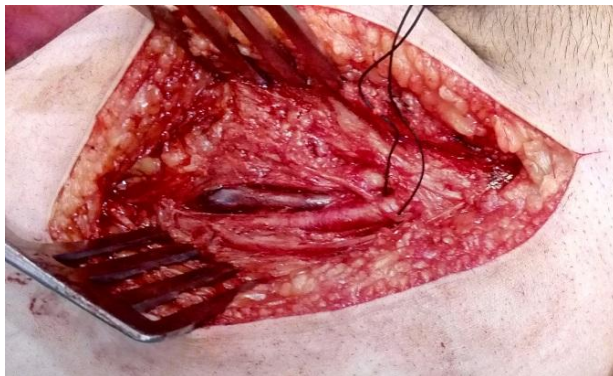With this PET CT findings we subjected patient for excision of the mass.

Intraoperatively it was found that tumour was very vascular and attached to Deep femoral vein which was excised in toto and sample was sent for histopathological examination.

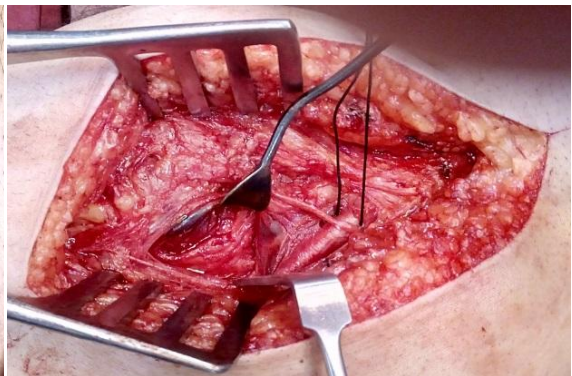
Histologically features suggestive of mesenchymal and vascular Tumor with low grade likely to be associated with hypophosphatemic rickets IHC was also done which was positive for S-100P and KL-67 and

diagnosed as benign spindle cells tumor consistent with phosphaturic mesenchymal tumour.

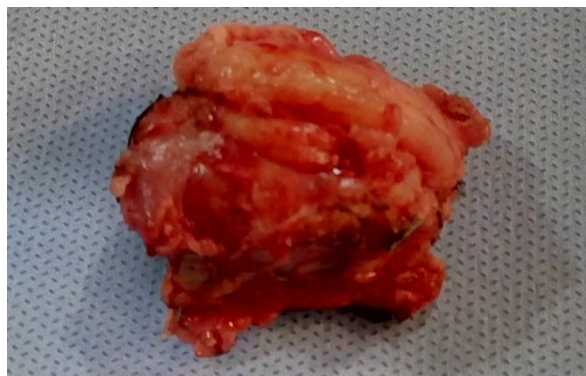On good successive follow up all lab parameters including FGF-23 levels came within normal limits at the end of 3 weeks and patient was declared free from hypophosphatemic rickets. Patient is now symptom free and resumed his all daily activities. (FGF-23-59.3 RU/L , serum phosphorus-5.60 mg%, alkaline phosphatase - 137.2mg%. Patient is not on phosphorus supplements).



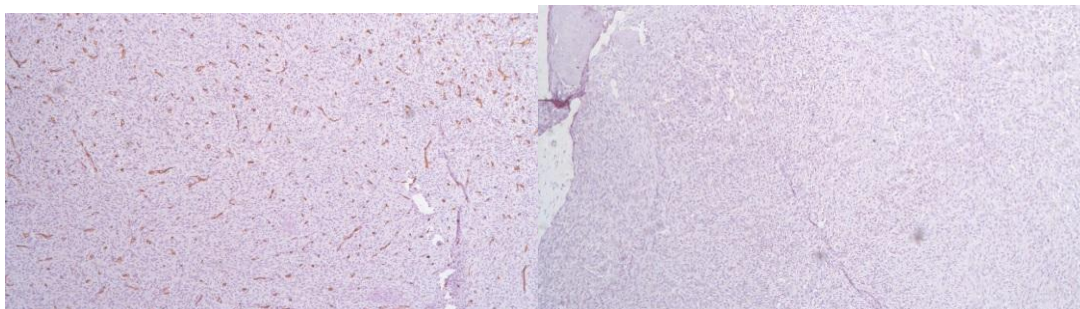
**Exposure of femoral vessels**



**lesion abutting femoral vein**



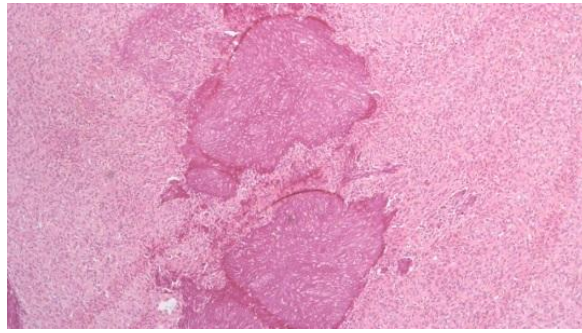
**Excised lesion**



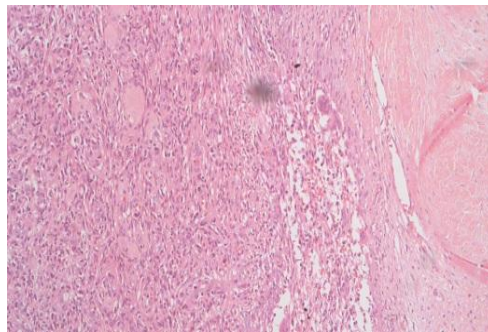
**CD 34 Negative**

**Desmin Negative**

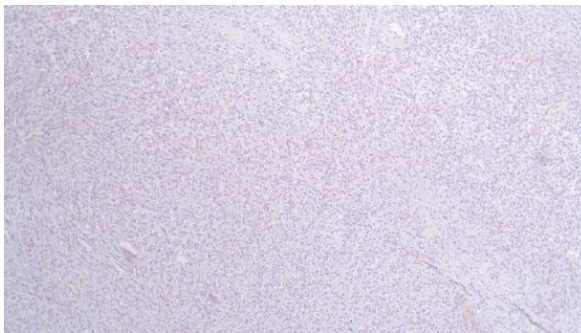




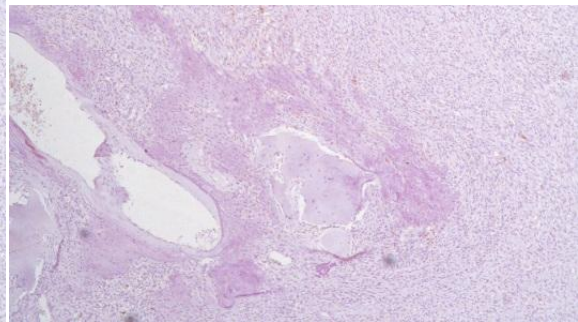
**Vascular components endothelial spindle cell proliferation**



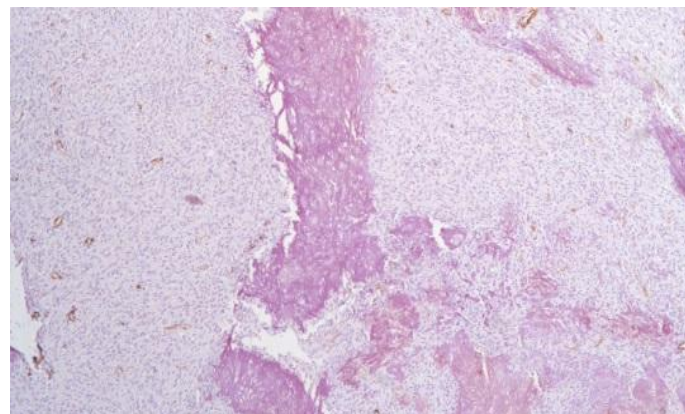
**Low power field - vascular and showing Mesenchymal elements**



**Ki - 67 Positive , <01%**



**s-100 p occasional cells Positive**



**Smooth muscle actin Negative**

### 3. DISCUSSION

Tumour induced osteomalacia is a rare paraneoplastic syndrome first describe by Dr Robert McCane@ with features of hypophosphatemia , myopathy, bone pain and fractures TIO is an acquired form of hypophosphatemia.

Ratio among male and female is 1:1. This disease presents usually at 4th and 5th decade of life. Prevalence of TIO is not known but till now 500 cases have been reported.

Almost all body regions are potentially affected by TIO. TIO presented with features ranging from weakness, difficulty in walking, loss of height, pathologic fractures in femur, vertebra, rounds pseudofractures of pubic rami and pelvic deformity. Suspicion of TIO arises when there is hypophosphatemia with hyperphosphaturia in non azotemic adult in absence of acidosis. Increased level of FGF-23 produced by the tumor it has been reported that OO associated with mesenchymal tumour over exprsees fgf23, there is inhibition of tubular reabsorption of phosphate which leads to hyperphosphaturia in TIO.

Meyer et al. and Nebitt et al.demonstrated circulating factor that could be responsible in sets of experiments over mice. Miyauchi el al supported this by transplanting human tumor in nude mice which causes hypophosphatemia [7]. There is increase in vessel size and vascular pattern which leads to increase in microvasculature in these tumors [1]. Differential diagnosis for these tumours are Hemangiopericytoma, hemangioma, sarcoma, ossifying fibroma, granuloma, giant cell tumors and osteoblastoma [1,2]. Osteocytes releases FGF-23 which is a peptide and it inhibits Na-Pi-11 transporter in intestine and kidneys leading to hypophosphaturia FGF-23 directly inhibits 1alpha hydroxylase expression which in turn inhibits activation of 25 judicial D to 1,25-dihydroxyvitamin D. Decreases level of 1,25-dihydroxyvitamin D leads to decreased intestinal absorption of phosphate. In the above mentioned patient very high level of FGF-23 confirmed TIO and patient very high level of FGF-23 confirmed TIO and PET scan localised the tumor. F-18 Fluorodeoxyglucose positron emission tomography with computed tomography is most sensitive for localising TIO tumors [8].

Mesenchymal tumour producing FGF-23 are generally benign and very small and difficult to

identify. Various imaging modalities have been enjoyed to localise FGF-23 producing tumors including hone scanning, CT,MRI Indium-111 pentreotide or octreotide scintigraphy and PET. Origin of these tumor is either from bone or soft tissue where around 40% arise from bone and 55% arise from soft tissue. 31% of these tumor are found in head and 56% are found in lower extremities. Since these tumors are found in varied locations so for localisation PET scan should be done first followed by conventional CT or MRI . TIO tumors are generally small and often present within bone and are difficult to locate PET/CT with Ga 68- DOTANOC is used for detection of NET (neuroendocrine tumours) is highly sensitive(90%) and specific(82%) [9].

Only solution of TIO to control phosphate wasting and symptoms is to resect the tumor [10]. This tumor recurs locally and can metastasize.

Phosphaturic mesenchymal tumour(PMTs) are classified into four types according to morphology 1) primitive aspirations mixed connective tissue tumor(PMTMCT) 2) osteoblastoma like tumors 3) non ossifying findings like tumors and 4) ossifying fibroma like tumors. PMTMCTs typically show Hemangiopericytoma like and aneuysmal come cyst like area [11].

### 4. CONCLUSION

TIO is a rare paraneoplastic tumor and causes hypophosphatemic osteomalacia due to over secretion of FGF-23. High index of suspicion in non responsive patients with stepwise approach involving various imaging techniques will help in successful diagnosis in 90% cases. Excision of tumor with wide margin is the treatment of choice.

### CONSENT

As per international standard or university standard, patients' written consent has been collected and preserved by the author(s).

### ETHICAL APPROVAL

As per international standard or university standard written ethical approval has been collected and preserved by the author(s).

### COMPETING INTERESTS

Authors have declared that no competing interests exist.

## REFERENCES

1. Folpe AL, Fanburg-Smith JC, Billings SD, Bisceglia M, Bertoni F, Cho JY, Econs MJ, Inwards CY, Jan de Beur SM, Mentzel T, et al. Most osteomalacia-associated mesenchymal tumors are a single histopathologic entity: an analysis of 32 cases and a comprehensive review of the literature. *American Journal of Surgical Pathology*. 2004;28:1–30.  
DOI: 10.1097/0000478-200401000-00001 [PubMed: 14707860]
2. Drezner MK. Tumor-induced osteomalacia. *Reviews in Endocrine & Metabolic Disorders*. 2001;2:175–186.  
DOI: 10.1023/A:1010006811394 [PubMed: 11705323]
3. Jan de Beur SM. Tumor-induced osteomalacia. *Journal of the American Medical Association*. 2005;294:1260–1267  
DOI: 10.1001/jama.294.10.1260 [PubMed: 16160135]
4. Saville PD, Nassim JR, Stevenson FH, Mulligan L, Carey M. Osteomalacia in Von Recklinghausen's neurofibromatosis; metabolic study of a case. *BMJ*. 1955;1: 1311–1313.  
DOI: 10.1136/bmj.1.4925.1311 [PubMed: 14363873]
5. Dent CE, Gertner JM. Hypophosphataemic osteomalacia in fibrous dysplasia. *Quarterly Journal of Medicine*. 1976; 45:411–420.  
[PubMed: 948543]
6. Collins MT, Chebli C, Jones J, Kushner H, Consugar M, Rinaldo P, Wientroub S, Bianco P, Robey PG. Renal phosphate wasting in fibrous dysplasia of bone is part of a generalized renal tubular dysfunction similar to that seen in tumor-induced osteomalacia. *Journal of Bone and Mineral Research*. 2001; 16:806–813.  
DOI: 10.1359/jbmr.2001.16.5.806 [PubMed: 11341325]
7. Miyauchi A, Fukase M, Tsutsumi M, Fujita T. Haemangiopericytoma –induced osteomalacia :tumor transplantation in nude mice causes hypophosphatemia and tumor extracts inhibit renal 25-hydroxyvitamin D1 –hydroxylase activity .*Journal of clinical Endocrinology and Metabolism* 1988;67:46-53
8. Dupond JL, Mahammedi H, Prie D, Collin F, Gil H, Blagosklonov O, Ricbourg B, Meaux-Ruault N, Kantelip B. Oncogenic osteomalacia: diagnostic importance of fibroblast growth factor 23 and F-18 fluorodeoxyglucose PET/CT scan for the diagnosis and follow-up in one case. *Bone*. 2005b; 36:375–378.  
DOI: 10.1016/j.bone.2005.01.001 [PubMed: 15777669]
9. Von Falck C, Rodt T, Rosenthal H, Langer F, Goesling T, Knapp WH, Galanski M. (68)Ga-DOTANOC PET/CT for the detection of a mesenchymal tumor causing oncogenic osteomalacia. *European Journal of Nuclear Medicine and Molecular Imaging*. 2008; 35:1034.  
DOI: 10.1007/s00259-008-0755-8 [PubMed: 18369618]
10. Clunie GP, Fox PE, Stamp TC. Four cases of acquired hypophosphataemic ('oncogenic') osteomalacia. Problems of diagnosis, treatment and long-term management. *Rheumatology*. 2000;39: 1415–1421.  
DOI: 10.1093/rheumatology/39.12.1415 [PubMed: 11136887]
11. McCance RA osteomalacia with loosers node due to raise resistance to vitamin D acquired about the age of 15 years .*Q J Med* . 1947;16:33-46

© 2021 Deshmukh and Phute; This is an Open Access article distributed under the terms of the Creative Commons Attribution License (<http://creativecommons.org/licenses/by/4.0>), which permits unrestricted use, distribution, and reproduction in any medium, provided the original work is properly cited.

Peer-review history:

The peer review history for this paper can be accessed here:  
<https://www.sdiarticle5.com/review-history/76893>