

Multiple Viral Co-infections in a Pediatric Patient of Acute Encephalitis Syndrome (AES) - An Unique Case Report

**Maneesh Kumar¹, Roshan Kamal Topno², Binod Kumar Singh³, Alka Singh³,
Major Madhukar⁴, Bheemarao Kamble³, Ganesh Chandra Sahoo¹,
Pradeep Das⁵ and Krishna Pandey^{4*}**

¹Department of Virology, ICMR-Rajendra Memorial Research Institute of Medical Sciences, Agamkuan, Patna-800007, India.

²Department of Epidemiology, ICMR-Rajendra Memorial Research Institute of Medical Sciences, Agamkuan, Patna-800007, India.

³Department of Pediatrics, Nalanda Medical College and Hospital, Agamkuan, Patna-800007, India.

⁴Department of Clinical Medicine, ICMR-Rajendra Memorial Research Institute of Medical Sciences, Agamkuan, Patna-800007, India.

⁵Department of Molecular Biology, ICMR-Rajendra Memorial Research Institute of Medical Sciences, Agamkuan, Patna-800007, India.

Authors' contributions

This work was carried out in collaboration among all authors. Authors MK, RKT, KP and BKS conceived and designed the study protocol and drafted the manuscript. Authors KP, AS and MM performed the case and report discussion. Authors BK, GCS, MM and MK managed the literature searches. Authors MK and GCS performed interpreted and analyzed the laboratory work. Authors PD, KP, RKT and AS managed the analyses of the study and proofread the manuscript. All authors read and approved the final manuscript.

Article Information

DOI: 10.9734/IJTDH/2020/v41i1930384

Editor(s):

(1) Prof. Charbell Miguel Haddad Kury, University of Rio de Janeiro, Brazil.

Reviewers:

(1) Emmanuel Ifeanyi Obeagu, Nigeria.

(2) Richard Lathe, University of Edinburgh Medical School, UK.

Complete Peer review History: <http://www.sdiarticle4.com/review-history/62997>

Case Study

Received 15 September 2020

Accepted 21 November 2020

Published 11 December 2020

ABSTRACT

The occurrence of viral co-infection is always a challenging issue in pediatrics which indicates underestimation of causal viral pathogens. A 6-year-old girl child from Patna had diagnosed a rare case of multi-viral co-infection in February 2020. She was manifested with oblivion along with high-

grade fever, weakness, nasal bleed, headache, and body ache. She had altered sensorium with mildly dilated pupils. Her three classical meningeal sign i.e. Kernig's sign, Brudzinski's sign, and nuchal rigidity were found positive. She clinically investigated with a strong suspicion of viral infectivity. Awfully, she was diagnosed with multi-viral co-infection including Japanese Encephalitis, Dengue, Chikungunya, Cytomegalovirus, and Rubella where as HSV and VZV detected borderline. The IgM detection for JE using the CSF sample was found equivocal. The infection was also confirmed by CECT brain scanning. She got proper medication including antiemetic, antipyretic, antiepileptic drugs, antibiotics, anti-viral drugs, and 20% Mannitol for reducing the intra cranial pressure. After medication under proper clinical supervision, she improved completely with any seizures and viral infections. She advised for follow-up after a month. Such occurrences of multi-viral co-infections deserve proper attention and awareness among the healthcare experts about the severity of drugs.

Keywords: *Acute encephalitis syndrome; multi-viral co-infection; central nervous system; viral pathogenesis; meningo-encephalitis.*

1. INTRODUCTION

The occurrence of viral co-infection under Acute Encephalitis Syndrome (AES) severely affects the central nervous system (CNS) due to viral invasion. The multi-viral co-infection widely influences the pattern of disease. In the course of such viral infection neurological disturbance and meningeal involvement occur. In the natural scenario, many viruses competitively interfere with each other in a host, leading to multi-viral co-infection. They might control the immune response, virus virulence, and cell death [1,2]. Children with their weak immunity are often detected with such multiple viral infections. The significance of the viral pathogenesis, its severity, and clinical outcome is not well understood [3]. To facilitate such a viral incident, the molecular techniques need to be taken into a confirmation after the clinical appearance of the infection. On the contrary with the viral agents, bacteria are usually associated with them to increase the disease severity and later worsen the scenario, despite any precise knowledge about the interaction between bacteria and viruses [4,5]. Herein, an unusual multi-viral disease condition was detected in a girl child who was associated with abnormal body movement and loss of consciousness.

2. CASE PRESENTATION

On February 18, 2020, a patient resident of Patna, Bihar presented with her 6-year-old girl admitted to PICU of Nalanda Medical College & Hospital, Patna, Bihar, India, with a history of three days of high-grade fever with rigor, headache, and one episode of nasal bleed. She vomited in the previous night and developed an altered sensorium. According to her parents, she had similar episodes of nasal bleeding 2 months

back and which resolved spontaneously. She became weak and loss of appetite since last week, body rashes, and abnormalities in body movement similar to seizures (Fig. 1). The patient had no significant history of ear discharge, head injuries, meningitis, and major illness in the past. The patient had no recent travel history outside the Patna district. She had usual developmental milestones and had no history of Japanese Encephalitis (JE) and other viral infections in the past. After taking a proper clinical history and detailed clinical examinations, she was admitted to the pediatric intensive care unit (PICU) for further serological investigation and management after taking informed consent from her parent.

2.1 Clinical Findings during a Presentation

On the day of admission, the patient had altered sensorium with higher and brisk deep tendon reflexes (DTR) and plantar reflexes were extensor. She had mildly dilated pupils reactive to light. The three classical meningeal sign i.e. Kernig's sign, Brudzinski's sign, and nuchal rigidity were positive. Other clinical findings were also observed i.e. high body temperature (103°F), heart rate (130/min), oxygen saturation level (96% at room air), respiratory rate (26/min), and low blood pressure (70/40 mmHg). However, the cardiovascular system (S1S2) and chest examinations were found normal. Besides, her mental status with the Glasgow Coma Scale (GCS) scores of 6/15. None of the family members had such a history of seizure or other neurological disorders.

2.2 Investigation

The patient underwent a Contrast Enhanced Computerized Tomography (CECT) scan of the

brain to detect any abnormalities (Fig. 2). The findings were suggestive of encephalitis with poorly enhanced hypodense areas in bilateral basifrontal and occipital region, and lesion at the posterior part of the cerebellar hemisphere. She had also prominent cistern magna.

The blood and CSF samples were sent to the Department of Virology, Rajendra Memorial Research Institute of Medical Sciences, Patna, Bihar, India for the detection of different viral infections. The serological analysis was performed by using ELISA test kit- JE IgM, Dengue IgM, Chikungunya IgM (NIV, Pune, INDIA), Herpes Simplex Virus (HSV) IgM, Cytomegalovirus (CMV) IgM, Rubella IgM, Varicella Zoster Virus (VZV) IgM, Measles (Calbiotech, USA), Hepatitis E virus (HEV) IgM (Promega). Interestingly, the patient's sample was IgM positive for JE, Dengue, Chikungunya, CMV, and Rubella whereas IgM borderline for HSV and VZV. The IgM detection for JE using the CSF sample was found equivocal. CSF cells, protein, sugar were within the normal range. The blood picture including Total leucocytes count,

Differential Leucocytes count, and Chest X-ray posterior view was normal. Blood for Malaria Parasite/Typhoid etc was negative and PCR for the MTB was negative. The Liver function test and renal function test were normal. All the serological confirmation of viral infection were further validated by using RT-PCR which also found positive (Fig. 3).

2.3 Management and Outcome

The patient was managed conservatively with the antiemetic drug (Ondesentron), antibiotics (Ceftriaxone, Vancomycin, Amikacin) and anti-viral drugs (Acyclovir) including antipyretic (Paracetamol), for reducing the intracranial pressure (20% Mannitol), antiepileptic (Phenytoin sodium), etc. The patient's health improved within two weeks. She was conscious with no meningeal sign. All the cranial nerves, motor nerves, and sensory nerves were also found normal. Her Glasgow Coma Scale found on the seventh day was 15/15. She was discharged on the tenth day with the advice to her parents for follow-up after one month.

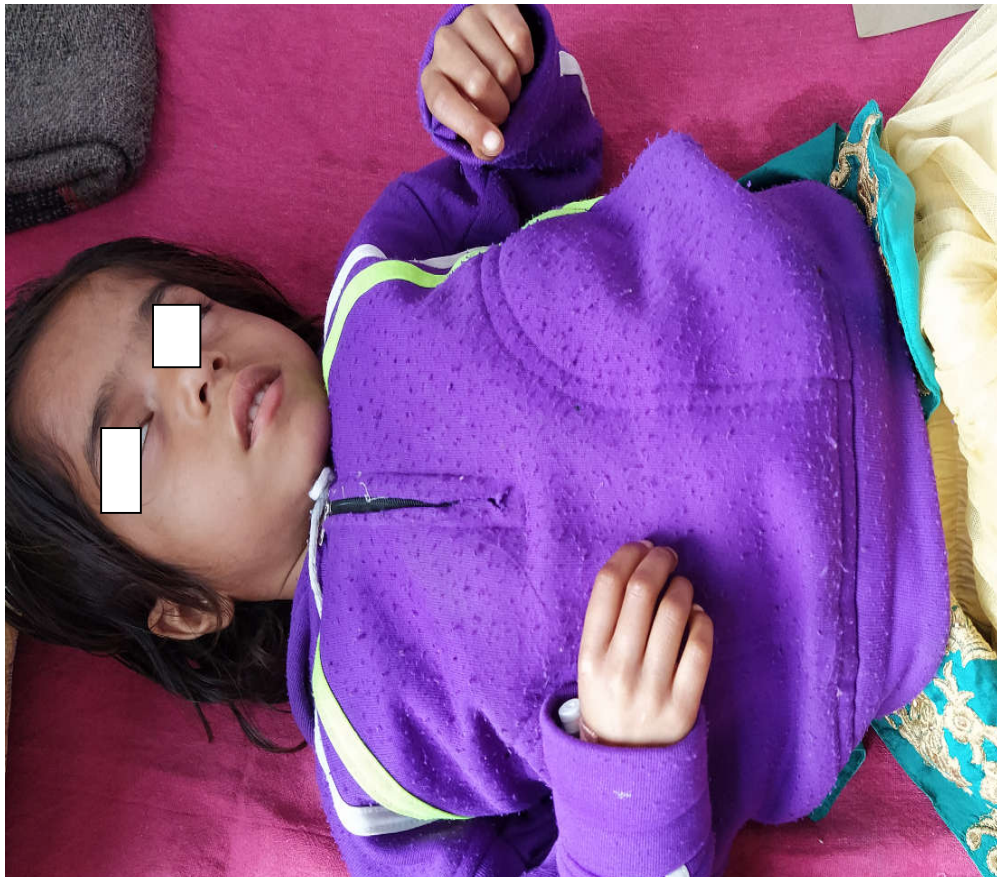

Fig. 1. The patient under unconscious condition

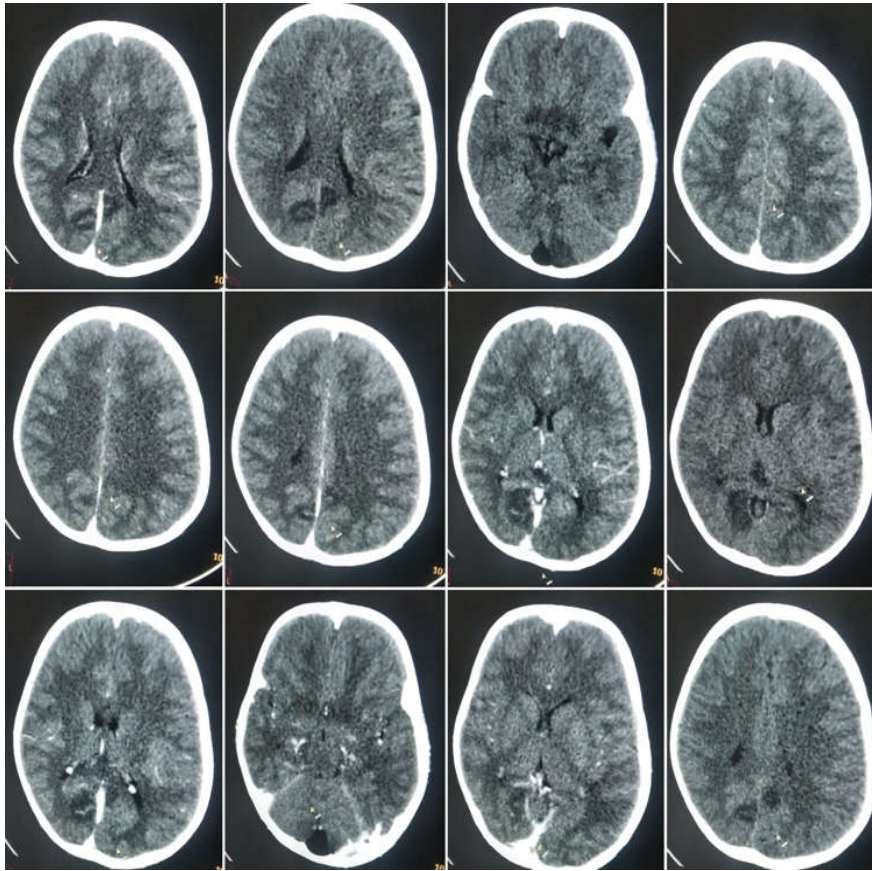


Fig. 2. CECT scan of brain

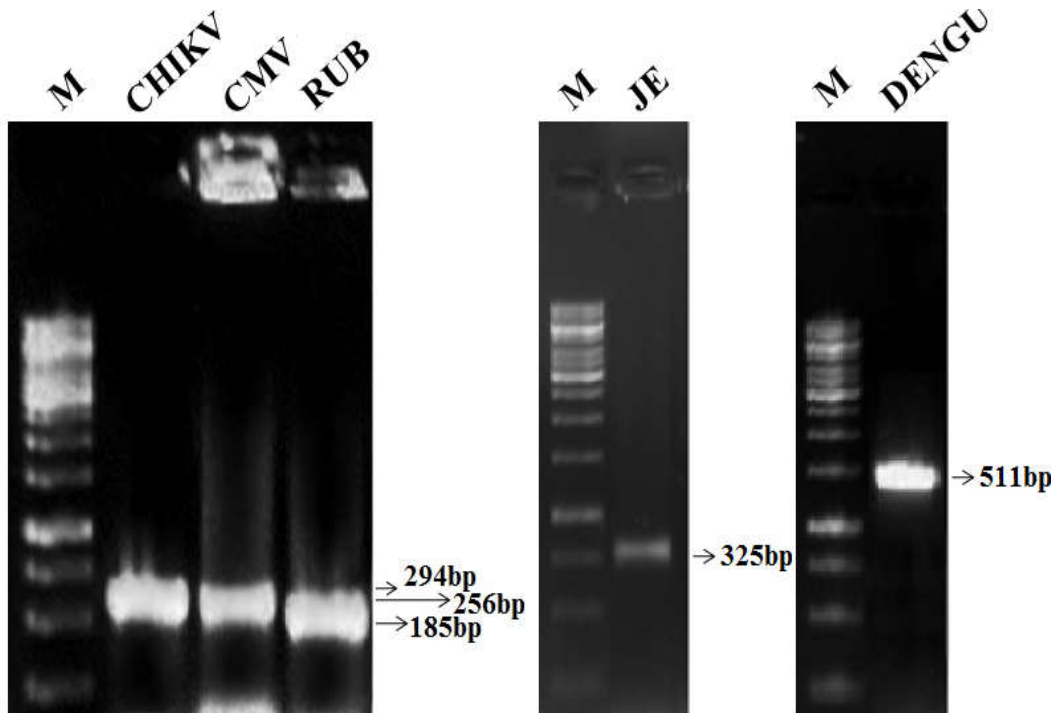


Fig. 3. RT-PCR confirmation of respective viral infections

3. DISCUSSION

This study confirmed a rare case of multi-viral co-infection in a single individual. Previously one case had been reported with multi-viral co-infection reported in a girl child [6]. Here, in this present case report, the patient was infected with five different viral agents. This is a case of severe neuro-inflammation that occurred in the case of Acute Encephalitis Syndrome (AES). The infections were present with JE, Dengue, Chikungunya, CMV, HSV-II, and Rubella. The initial presentations were fever, headache, vomiting, neck rigidity, and loss of consciousness with generalized tonic-clonic convulsion. This creates neurotropic activities within the CNS and potentially worsen neurological situation during the infectivity period. These viral agents present with complicated sequelae occur if delayed the diagnosis and clinical management [7].

The patient had initially a Glasgow Coma Scale (GCS) of 6 (E=2, V=2, M=2) but recovered after treatment. The treatment was initiated with 20% Mannitol, Normal Saline (NS), Injection Ceftriaxone, Injection Vancomycin, and Acyclovir (10 mg per kg body wt thrice a day in NS). An anti-epileptic drug such as Phenytoin Sodium was also administered for seizures. All these medications were given in the PICU setting. Besides these, oxygen was also administered. The GCS improved to 10 on the fourth day and 15 on the seventh day. The patient started sitting up from the seventh day and was discharged on the tenth day without any sequelae. To our knowledge, this is the first case report in which multiple infections occurred in a single case of AES. The treatment included supportive such as Mannitol to reduce Intra-cranial pressure and IV fluids along with antibiotics and antiviral treatment. The prognosis in these types of patients was extremely poor but astonishingly in this case there was a favorable outcome. The neurological manifestations due to attack of various viral are rare and inconstant. The occurrence of such multi-viral co-infection plays a significant role in the disease severity. The interference of many viral pathogens at a time usually influences the replication of each other. This may lead to the persistence of one over another viral infection [8,9]. During the investigation of the viral interference, clinical symptoms were widely taken into consideration with the involving pathogens, for clinical insinuation, diagnosis, and therapeutic management [10]. Finally, the diagnosis was

established as a case of meningo-encephalitis with multiple viral pathogenic infections.

4. CONCLUSION

The incidence of viral confections with two or three etiological agents is not very uncommon and is generally related to respiratory tracts or with some bacterial infections. Here, in this case, the multi-viral co-infection case, five different viral pathogens could rarely present with various classical meningeal signs. The patient's neurological behavior with prominent cistern magna worsens the condition during the multi-viral infectivity. With all the clinical and laboratory confirmation, the child patient was treated well under proper medication. She recovered after three weeks. She advised for the follow-up after a month. The concern is needed to be given at a molecular and immunological level to explore the basic reasons for such multi-viral co-infection and awareness too.

CONSENT

After taking a proper clinical history and detailed clinical examinations, she was admitted to the pediatric intensive care unit (PICU) for further serological investigation and management after taking informed and written consent from her parent.

ETHICAL APPROVAL

It is not applicable.

COMPETING INTERESTS

Authors have declared that no competing interests exist.

REFERENCES

1. Kumar N, Sharma S, Barua S et al. Virological and immunological outcomes of coinfections. *Clin Microbiol Rev.* 2018;1:31(4). DOI: 10.1128/CMR.00111-17
2. Kuma M, Topno RK, Dikhit MR et al. Molecular docking studies of chloroquine and its derivatives against P23pro-zbd domain of chikungunya virus: Implication in designing of novel therapeutic strategies. *J Cell Biochem.* 2019;120(10):18298-18308. DOI: 10.1002/jcb.29139 [PubMed: 31310373]

3. Cebey-López M, Herberg J, Pardo-Seco J et al. Does viral co-infection influence the severity of acute respiratory infection in children? PLoS One. 2016;11(4): e0152481.
DOI: 10.1371/journal.pone.0152481
[Pubmed: 27096199]
4. Rhedin S, Lindstrand A, Rotzén-Östlund M et al. Clinical utility of PCR for common viruses in acute respiratory illness. Pediatrics. 2014.1;133(3):e538-545.
Doi: 10.1542/peds.2013-3042
[Pubmed: 24567027]
5. Kumar P, Mishra R, Topno RK et al. Seasonal Prevalence of Japanese Encephalitis (JE) in Patna District of Bihar, India. J Commun Dis. 2020;51(4):58-61.
DOI:https://doi.org/10.24321/0019.5138.201937
6. Kumar M, Topno RK, Pandey K et al. Acute encephalitis syndrome child patient with multi-viral co-infection: A rare case report. Journal of Medical & Allied Sciences. 2019;9(2):100-102.
DOI: 10.5455/jmas.23328
7. Bechter K. Virus infection as a cause of inflammation in psychiatric disorders. In Inflammation in Psychiatry. 2013;28:49-60.
Doi: 10.1159/000343967.
[Pubmed: 25224890]
8. Kumar N, Barua S, Riyesh T et al. Complexities in isolation and purification of multiple viruses from mixed viral infections: Viral interference, persistence and exclusion. PLoS One. 2016;26:11(5): e0156110.
DOI: 10.1371/journal.pone.0156110
[Pubmed: 27227480]
9. Dinesh DS, Topno RK, Pandey K, et al. Chandipura virus recognized among AES for the first time in Bihar, India. Int J Curr Microbiol Appl Sci. 2018;7(12):3658-3663.
DOI:https://doi.org/10.20546/ijcmas.2018.712.414
10. Topno RK, Pandey K, Singh BB et al. Viral etiological factors causing acute encephalitis syndrome (AES) In Gaya Division, India. Hospital Practices and Research. 2019;4(3):92-6.
DOI: 10.15171/HPR.2019.18.

© 2020 Kumar et al.; This is an Open Access article distributed under the terms of the Creative Commons Attribution License (<http://creativecommons.org/licenses/by/4.0>), which permits unrestricted use, distribution, and reproduction in any medium, provided the original work is properly cited.

Peer-review history:

*The peer review history for this paper can be accessed here:
<http://www.sdiarticle4.com/review-history/62997>*