



A Study of Functional Outcome of Bimalleolar Fracture

Nitin S. Patil¹, Nishant K. Gaonkar^{1*}, Shrikant K. Dalal¹ and Avate Shivaji¹

¹Department of Orthopaedics, Krishna Institute of Medical Sciences, Karad, Maharashtra-415110, India.

Authors' contributions

This work was carried out in collaboration among all authors. All authors read and approved the final manuscript.

Article Information

DOI: 10.9734/JPRI/2020/v32i3030904

Editor(s):

(1) Dr. Thomas F. George, University of Missouri- St. Louis and University Boulevard St. Louis, USA.

Reviewers:

(1) Amit Sangwan, Lala Lajpat Rai University of Veterinary and Animal Sciences, India.

(2) Zunuwanas Bin Mohamad, Politeknik Bagan Datuk, Malaysia.

Complete Peer review History: <http://www.sdiarticle4.com/review-history/62176>

Original Research Article

Received 20 August 2020
Accepted 23 October 2020
Published 25 November 2020

ABSTRACT

The results of bimalleolar ankle fractures are better with emphasis on anatomical reduction of fracture, stable internal fixation, regaining full fibular length and early active pain free mobilization, since the advent of A.O principles of management. This study analyzes the functional outcome of Ankle joint after Internal Fixation of bimalleolar fracture. This study was done to evaluate the functional outcome of ankle joint after internal fixation of bimalleolar fracture, those which were operated with different modalities. Classifications used were Lauge-Hansen Classification and Danis-Weber Classification. Road traffic accident, Twisting injury and Fall from height were major mode of injury. Cannulated cancellous screw, Malleolar Screw and TBW used for medial malleolus and semi tubular plate, cannulated cancellous screw and Rush Nail used for fibula are common mode of fixation. According to Baird and Jackson scoring system out of 40 cases, 92.5% were excellent and good, 5% were fair and 2.5% were poor. Anatomical correlations suggest reduction and stable internal fixation restore the articular congruity of ankle joint results in high percentage of excellent and good results.

*Corresponding author: E-mail: dr.ngaonkar@gmail.com;

Keywords: *Bimalleolar ankle fracture; Lauge-Hansen; Danis Weber; Baird and Jackson scoring system.*

1. INTRODUCTION

Ankle joint is usually highly susceptible to injuries. This is because it is relatively mobile and bear much of the stresses associated with weight bearing. The ankle joint supports more weight per unit area than any other joint in the body [1]. Many of the ankle injuries are both bony and ligamentous components. Magnetic resonance imaging nowadays is useful for diagnosing ligamentous injury and repairing, while treating this fracture. The French had written extensively on ankle injuries beginning with Baron, Dupuytren and then Maisonneuve, but it was not until 1922 that a proper understanding of Classification and the Mechanism of the ankle fractures was published in a paper by Ashurst and Bromer [2,3].

1.1 Research Objectives

To Evaluate the Functional outcome of Ankle Joint after internal fixation of bimalleolar fracture. To analyze the Ankle Function after internal fixation of bimalleolar fracture at the end of 6 months – a) Time required for union with respect to clinical and Radiological outcomes. b) Range of movements. c) Functional scoring system (Baird and Jackson) – Analyzing Pain Stability of ankle, Able to run, walk as well as work, Motion of the ankle, Radiographic result, etc.

2. HISTORICAL REVIEW

Large contributions were made by many authors for the mechanism of production of injuries around ankle about three centuries ago. In olden times injuries around ankle were diagnosed as subluxations or dislocations. It was Percival pott in 1768 who first described injuries around ankle. He first described a fracture of fibula within 2 or 3 inches of its lower extremity associated with deltoid ligament tear and talus lateral subluxation [4].

In 1839 DUPUYTREN demonstrated the role of inward and outward movement of the foot in ankle injuries, distinguishing fractures caused by talar impact and those by ligamentous avulsion. By outward movement of the foot he demonstrated the fibular fracture observed by

pott. He was first to describe proximal talus dislocation following diastasis and to identify rupture of tibio fibular ligaments which is a common accompaniment of this fracture. In 1840 MAISONNEUVE described pronation-external rotation type of ankle injury and proved it was determined by the strength of syndesmosis. He emphasized the ankle injury with fracture of proximal third of the fibula and distinguish it from direct trauma to fibula [5,3].

In 1890 ROCHE demonstrated vertical compression was necessary to produce marginal fractures of distal fibula which was first described by ASTLEY COOPER. With the innovation of x-rays in 20th century, the study on ankle fractures added a new dimension. DESTOT named posterior lip of tibia as third malleolus. In 1912 COTTON drew attention to posterior malleolus fracture [6].

In beginning of this century, LANE pioneered in the operative treatment of ankle fractures. He employed no-touch surgical technique and preferred screw fixation of fracture fragments. The biodegradable implants are now being used in some centers for the fixation of bimalleolar ankle fractures. The degradation within the body by hydrolysis is between 2 months to 6 months [7].

2.1 Mechanics of the Ankle Joint

Ankle joint is relatively strong and stable joint. This is required for maintaining erect postures. Ankle joint is also required in push off phase and absorbing loading while walking, running etc.

2.1.1 Stability of ankle

Socket shape of ankle joint and strength of the surrounding structures make joint stable and strong. This stability depends on following structures primarily-

1. Medial malleolus with medial collateral ligament.
2. Lateral malleolus with lateral collateral ligament.
3. Anterior syndesmotomic ligament.
4. Posterior syndesmotomic ligament and posterior malleolus.

In case of malleolar fractures, more the number of these structures are injured, stability of ankle is reduced [7]. If the syndesmosis and fibula both are disrupted, 2-3 mm lateral shift of the talus can occur even if deep deltoid ligament is intact [8]. Rotational stability of ankle is due to congruency of articular surfaces.

2.1.2 The ring of ankle mortise

Since most ankle injuries are produced by abnormal motion of talus, the talus may be said to be the ring leader. For talar shift to occur, there must be atleast two breaks in the ring; either a fracture of both malleoli or a fracture of one malleolus and rupture of one ligament [9]. This fact is important in assessing the stability or potential for displacement of any ankle injury (Fig. 1).

2.1.3 Loading and load distribution

During vigorous exercises ankle joint sustains load as high as 4 to 5 times the body weight [10]. This loading keeps talus in anatomical position thus enhancing stability. Under loading, joint contact area increases by almost 100%. This increases stiffness as compared to unloaded condition. Normally $1/6^{\text{th}}$ of the weight is

transmitted proximally through fibula and $5/6^{\text{th}}$ through tibia [11].

2.2 Preoperative Care and Planning

The patients who were presented in the casualty and out-patient department were examined clinically and radiologically. Closed reduction and immobilisation with plaster of Paris was done for all cases. Check x-rays were taken and planned for surgery accordingly. High quality radiographs helps in planning for reduction and choosing proper implants. Radiographic views of contralateral ankle are taken in few cases for comparison. The size and position of the malleolar fragment and involvement of distal tibio-fibular joint was assessed by computed tomography was done in four cases. Magnetic resonance imaging to assess soft tissue injury and ligamentous involvement was done in seven cases and is useful to obtain good functional outcome. Displacement and stability of the fracture was assessed by X-rays. In displaced fracture reduction was done immediately to maintain tibiotalar congruity. Stress radiographs were done in ten cases to assess preoperative syndesmotic injury. In syndesmotic instability Shenton's line broken and Dime sign\Ball sign present.

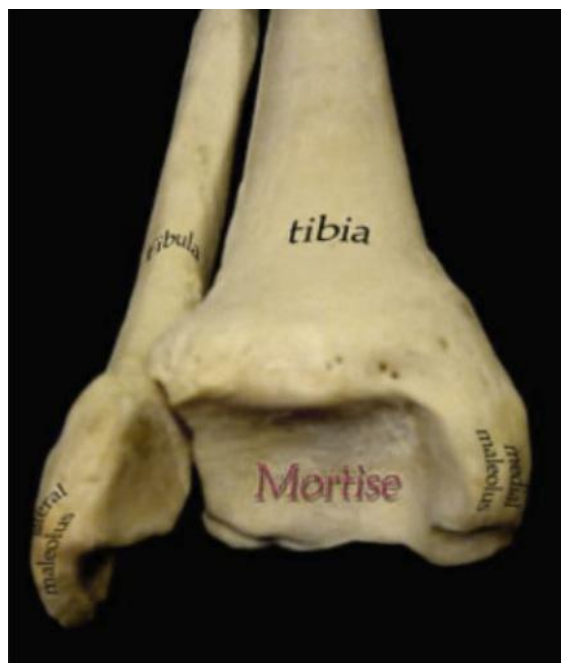

Fig. 1. Ankle mortise

3. METHODOLOGY

This study was done to evaluate the functional outcome of ankle joint after internal fixation of bimalleolar fracture, those who are operated with different modalities. This is a prospective study (from November 2016 to March 2018) of 40 patients treated at Krishna hospital and Medical research center, Karad. It includes the patients presenting themselves in casualty and OPD of Department of orthopaedics and newly diagnosed as bimalleolar fractures. Maximum Follow up period was 6 months after operative management.

Necessary routine investigations were carried out. The diagnosis was confirmed by antero-posterior, lateral and mortise radiographs. Stabilization was done with a below knee slab, and Open reduction and internal fixation (ORIF) was done once the skin condition was good and swelling had subsided.

3.1 Inclusion Criteria

1. Age above 18 years.
2. Patients of either sex.
3. Patients having bimalleolar fracture of either ankle joint.
4. Patients who are fit for surgery.
5. Patients fulfilling the above-mentioned criteria and willing to participate in this study.

3.2 Exclusion Criteria

1. Age below 18 years.
2. Unwillingness to participate in the study.
3. Patients unfit for surgery and/or anaesthesia.
4. Patients with history of previous bimalleolar fracture of either ankle.
5. Pilon fracture.
6. Trimalleolar fracture.

The basic idea was to achieve near anatomical reduction. ORIF was used in all 40 patients. It was done as a planned and elective procedure. Before patients were taken up for surgery, they were put on foot elevation and anti-inflammatory drugs for few days to reduce ankle swelling. Post-operatively limbs were immobilized in plaster splint, patients were put on antibiotics and analgesics and limbs were elevated. Dressings were done regularly and sutures were removed on average on 15th day (decided according to the wound inspection). The below knee splint was continued or cast was done till 6 weeks of

postoperative and was then removed. Patients were assessed for fracture union radiologically. Once the fracture showed signs of union, partial weight bearing was advised, which was approximately at 6-8 weeks and it was then gradually increased to full weight bearing. Physiotherapy exercises for ankle movements were started on removal of slab or cast.

3.3 Assessment of Results

Baird and Jackson scoring 59 system was used to evaluate the patients at the end of 6th month. Finally, correlation between results of the score and clinical data were used to evaluate functional outcome of ankle joint after internal fixation of bimalleolar fracture.

3.4 Statistical Analysis

The Excel and GraphpadInstat (Graphpadsoftwaresinc, USA) software packages were used for data entry and analysis.

3.4.1 Implants used for fixation

3.4.1.1 For lateral malleolus

- a) One third tubular plate –20
- b) Rush Nail-10
- c) Cannulated Cancellous screw-09
- d) Tension band wiring – 01

3.4.1.2 For medial malleolus

- a) Cannulated Cancellous Screws –24
- b) Tension Band Wiring –12
- c) Semi tubular plate- 02
- d) Malleolar screw -02

Intramedullary fixation offers a minimally invasive approach to the distal fibula with little palpable metalwork. Initially popular intramedullary implants, such as Rush nails (2 mm, 2.5 mm, 3 mm, 3.5 mm or 4 mm) were smooth devices with no fixation to bone and were predisposed to backing out, therefore not controlling fibular length or preventing talar shift. Despite this, functional outcomes were excellent or good with no complications. To reduce the problems of backing out, 4.0 mm partially threaded cannulated cancellous screw or TBW were reported good results in patients with minimal fracture comminution.

4. RESULTS AND DISCUSSION

This was a prospective study includes of 40 cases of bimalleolar ankle fractures who were

treated surgically at Krishna medical college and hospital, Karad from November 2016 to March 2018. Distribution of patients in Table 1.

Table 1. Sex distribution of patients

Sex	No. of patients
Male	23 (57.5%)
Female	17 (42.5%)

Out of total 40 patients, Age distribution for age 18-28 is 5 patients (12.5%), 29-38 is 7 patients (17.5%), 39-48 is 9 patients (22.5%), 49-58 is 8 patients (20%), 59-68 is 8 patients (20%) and 69-78 is 3 patients (7.5%). The mean age was 46.775 and the standard deviation was 15.432 in Table 2.

Injury was more common in males – 23 (57.5%) as compared to females -17 (42.5%).

Out of 40 patients, the most common injury pattern seen in our study was SER type injury – 20 patients (50%), followed by SAD type were – 13 patients (32.5%), PER type were 6 patients

(15%) and PAB type were 1 patient (2.5%). SER was found to be most common as p-value is significantly less than 0.0001 and Chi-Square value is 27.467 in Table 3.

Out of 40 patients, Danis Weber type B was found to be most common – 20 patients (50%), Type A was found in 13 patients (32.5%) and type C was found in 7 patients (17.5%). Thus, Type B was found to be most common as p-value is significant 0.0085 and Chi square value is 9.525 in Table 4.

In this study, at the end 6 weeks, the Plantarflexion mean range was 13.75° and Dorsiflexion mean range was 7.75°. In this study, at the end of 6 months, the Plantarflexion mean range was 32.875° and Dorsiflexion mean range was 19° (Fig. 2).

Out of total 40 patients in our study, SER injury is most common type of bimalleolar ankle fracture as p value is significantly less than 0.0001, chi square value is 27.467 and mean Baired score is 92.45 (see also Fig. 3).

Table 2. Age distribution of patients

Age	Patients	Mean	Standard deviation
18-28	5 (12.5%)	46.775	15.432
29-38	7 (17.5%)		
39-48	9 (22.5%)		
49-58	8 (20%)		
59-68	8 (20%)		
69-78	3 (7.5%)		

Table 3. Source of injuries

Source of injury	No. of patients
Road traffic accidents	29 (72.5%)
Twisting injury	8 (20%)
Fall from height	3 (7.5%)

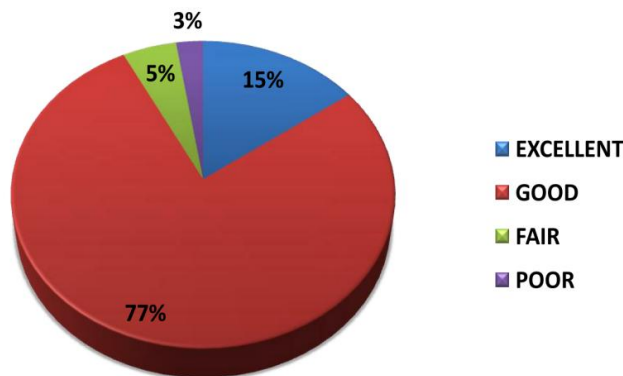


Fig. 2. Functional outcome by Baird and Jackson scores at the end of 6 months

Table 4. Functional outcomes of fracture pattern

Type of injury	No. of cases	Mean Baird score	No. of complications	Chi-square value	p value
SER	20 (50%)	92.45	1	27.467	<0.0001
PER	6 (15%)	94.33	0		
SAD	13(32.5%)	93.23	3		
PAB	1 (2.5%)	97	0		

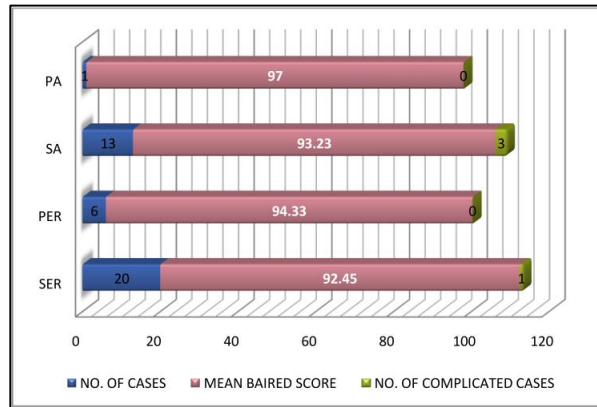


Fig. 3. Functional outcomes of fracture pattern

5. CONCLUSION

In this study it was observed that Bimalleolar fracture treated with ORIF gain Excellent to Good Ankle function after 6 month by using Baird and Jackson scoring system. Supination-external rotation type of injury was common. The Frequency of Pronation-external rotation and Pronation abduction type of injury was less. The Anatomical reduction and stable internal fixation restore the articular congruity of ankle joint results in excellent to good functional outcome and help in early mobilization after surgery.

CONSENT AND ETHICAL APPROVAL

As per university standard guideline, participant consent and ethical approval have been collected and preserved by the authors.

ACKNOWLEDGEMENTS

Authors would like to thank Department of Orthopaedics, Krishna Institute of Medical Sciences, Karad, Maharashtra, India.

COMPETING INTERESTS

Authors have declared that no competing interests exist.

REFERENCES

- Roy I, Davidovitch, Egol AK. Ankle fractures. In: Bucholz WR, Charles, Heckman JD, Paultornetta, Editors. Rockwood and greens fractures in adults. Edition 7. Philadelphia: Lippincott Williams and Wilkins Publishers. 2009;1975-2017.
- Simon WH, Friedenbunrg S, Richardson S. Joint congruence; A correlation of joint congruence and thickness of articular cartilage in cogs. J Bone Joint Surg. 1973;55:1614.
- Gaurav S, Gunaki RB, Patil V, Garud AB. A study of functional outcome of bimalleolar fracture after internal fixation. International Journal of Orthopaedics. 2019;5(1):64-69.
- Shelton Marvin L. Complication of fractures and dislocation of the ankle. In: Complications in Orthopaedic Surgery, Chapter 23, 3rd Edn., Vol. I, Edit. EPPS, Charles H, Philadelphia: J.B. Lippincott Company. 1994;595-648.
- Ahmad Hafiz Z, Nazri MY, et al. Ankle fractures: The operative outcome. Malaysian Orthopaedic Journal. 2011;5: 40-43.
- Bartoníček J, Rammelt S, Tuček M, Naňka O. Posterior malleolar fractures of the ankle. European Journal of Trauma and Emergency Surgery. 2015;41(6):587-600.

7. Stephen A. Parada, James C. Krieg, et al. Bicortical fixation of medial malleolar fractures. *The American Journal of Orthopedics*. 2013;90-93.
8. CV DM, Venugopal N, Nanjundappa HC, Siddalinga Swamy MK. Bimalleolar fracture of ankle joint managed by tension band wiring technique: A prospective study. *Sch. J App. Med. Sci*. 2014;2(1D):428-32.
9. Pradeep Choudhari, Ranjeet Agrawal. Comparative study of one versus two screws in treatment of isolated fracture of medial malleolus. *International Journal of Current Medical and Applied Sciences*. 2015;52(3):151-154.
10. Parvataneni Prathap DA, Kondlapudi A, Hariprasad S. Functional outcome in surgical management of Bi-malleolar fractures in adults. *International Journal of Orthopaedics*. 2016;2(4):72-6.
11. Malhotra K, Welck M, Cullen N, Singh D, Goldberg AJ. The effects of weight bearing on the distal tibiofibular syndesmosis: A study comparing weight bearing-CT with conventional CT. *Foot and Ankle Surgery*. 2019;25(4):511-6.

© 2020 Patil et al.; This is an Open Access article distributed under the terms of the Creative Commons Attribution License (<http://creativecommons.org/licenses/by/4.0>), which permits unrestricted use, distribution, and reproduction in any medium, provided the original work is properly cited.

Peer-review history:

The peer review history for this paper can be accessed here:
<http://www.sdiarticle4.com/review-history/62176>