



Chemotherapy Induced Melanonychia: A Case Report

Foluke Atinuke Fasola^{1,2*} and Oladapo Wale Aworanti¹

¹*Department of Haematology, University College Hospital, Ibadan, Nigeria.*

²*Department of Haematology, College of Medicine, University of Ibadan, Nigeria.*

Authors' contributions

This work was carried out in collaboration between both authors. Author OWA made the draft of the manuscript. Authors FAF and OWA managed the literature searches. Author FAF managed literature searches and the correction of the draft. Both authors read and approved the final manuscript.

Article Information

DOI: 10.9734/IJMPCR/2016/28257

Editor(s):

(1) Jignesh G. Patel, Department of Pathology, University of Texas Medical Branch at Galveston, Texas, USA.

Reviewers:

(1) Alfred Chikweto, St. George's University, Grenada, West Indies.

(2) Anonymous, Sidra Medical and Research Center, Doha, Qatar.

(3) Nigel P Murray, University Finis Terrae, Chile.

(4) Shubhangi V. Agale, Grant Govt Medical College, Mumbai, India.

Complete Peer review History: <http://www.sciencedomain.org/review-history/16304>

Case Report

Received 12th July 2016
Accepted 6th September 2016
Published 23rd September 2016

ABSTRACT

Melanonychia during chemotherapy has been reported in many patients following several doses of certain cytotoxic drugs. Though a mild complication, it may cause anxiety for the patient. We report a patient who developed melanonychia after first dose of cyclophosphamide and vincristine. The patient developed transverse black pigmentation of the nail fingers which started proximally and spread distally to involve all fingernails sparing the toenails. The development of melanonychia associated with chemotherapy is not dose or duration of chemotherapy dependent. However, it should be distinguished from serious causes that may require biopsy and medical intervention.

Keywords: Melanonychia; chemotherapy; fingernail; cyclophosphamide.

*Corresponding author: E-mail: folukefasola@yahoo.com;

1. INTRODUCTION

Chemotherapy is the treatment of diseases using chemical agents. The use of the chemotherapy to treat malignant diseases may be local or systemic. This is unlike radiation therapy and surgery which are used as localized treatment. Chemotherapy, when used as systemic treatment, it affects not only the malignant cells but normal cells. Chemotherapeutic agents interfere with cell division through various mechanisms of action. The mechanisms include: impairing mitosis, targeting cancer cell enzymes, hormones and nutrient source to destabilize its growth, inhibiting formation of new blood vessels and apoptosis. The damage to normal cells results in varying severity of complications. While some complications are life threatening, some are of no consequence and are indicative of previous exposure to certain drugs. Nail changes are complications that are not life threatening but could cause anxiety for the patient with cosmetic concerns.

Nail toxicity is a relatively uncommon adverse effect linked to a number of chemotherapeutic agents [1]. Nail changes occur more frequently in patients undergoing chemotherapy with epidermal growth factor receptor inhibitor, taxanes and anthracyclines [2]. There are different types of nail changes seen in chemotherapy use [3]. Chemotherapy induced nail pathologies include different patterns of nail discoloration (known as chromonychia), beau's lines (transverse depression in the nail plate secondary to temporary cessation of nail growth), leukonychia (including Mee's and Muehrcke's lines), growth reduction, onycholysis (distal separation of the nail plate from the nail bed), onychodystrophy, onychodermal bands (onychodermal band is the seal between the nail plate and the hyponychium), paronychia (an infection that develops along the edge of the fingernail or toenail), subungual abscess and subungual hematoma [3,4]. Mees' lines are transverse lines (usually one, non-blanchable bands per nail, no depressions) due to sudden toxic damage to the nail matrix resulting in abnormal keratinization causing altered light diffraction in retained parakeratotic onychocytes [4]. Muehrcke lines are paired, white, transverse lines that signify an abnormality in the vascular bed of the nail.

We present a brief report of one of our patients with nail changes observed during chemotherapy.

2. CASE REPORT

A 37 year old computer sales man initially presented at ENT clinic of our hospital on account of left sided neck mass which was noticed about 6 months prior to presentation. The swelling was initially the size of the tip of the finger but gradually increased to the size of a tennis ball, with associated breathlessness and difficulty in swallowing. Examination at presentation, showed a young man, who was anicteric, afebrile, acyanosed, not pale, with normal nail colour and morphology and bilateral neck swelling; the neck swelling measured about 2 cm by 2 cm by 2 cm on the right side of the neck and 4 cm by 4 cm by 2 cm on the left. Examination of the oral cavity revealed tonsillar enlargement obstructing his airway. Bone marrow aspiration showed infiltration of the marrow by small size mononuclear cells identified to be lymphoid.

Biopsy and histology of the left tonsillar tissue was reported as diffuse small lymphocytic lymphoma. Erythrocyte Sedimentation Rate was 140 mm/hr-1, full blood count revealed a packed cell volume of 26%, white cell count of 4,400/mm² and platelet count was 425,000/mm². The electrolyte, urea, creatinine, uric acid, calcium, phosphate and liver function test were within normal ranges. Urinalysis did not show any abnormalities. A final diagnosis of stage IV diffuse small lymphocytic lymphoma was made. Based on the diagnosis, he was subsequently commenced on chemotherapy (CVP) – intravenous cyclophosphamide at 750 mg per m² day 1, intravenous vincristine at 1.4 mg per m² maximum 2 mg day 1, and oral prednisolone at 40 mg per m² days 1-5 as a 21 day cycle. Following 2 cycles of CVP without significant response, the regimen was changed to anthracycline containing chemotherapy- Cyclophosphamide, Daunorubicin, Oncovin and Prednisolone (CHOP). On completion of 1st cycle of the first chemotherapeutic regimen (CVP), patient reported black pigmentation of all fingernails units, which appeared as black transverse bands and streaks, initially involved the proximal aspect of nails but the severity and intensity increased as the frequency of exposure to chemotherapy increased. A diagnosis of chemotherapy induced melanonychia was made. The colour change subsequently involved the entire breadth of the nails, extending to half of the nail length by the end of 2nd dose of CHOP regimen. The toe nails were spared and skin

changes were not observed. No other complication of drugs was observed.

There was no associated history of pain or swelling at the nail beds, no preceding history of trauma to the nails, no fever, no differential warmth, no concurrent use of antiretroviral agents, no contact with dyes or chemicals and no recent change in job. Patient was reassured of the transit nature of this manifestation. Though patient did not respond to therapy, no other toxicity was observed. The patient died of progressive disease as disease progressively involved other organs of the body.

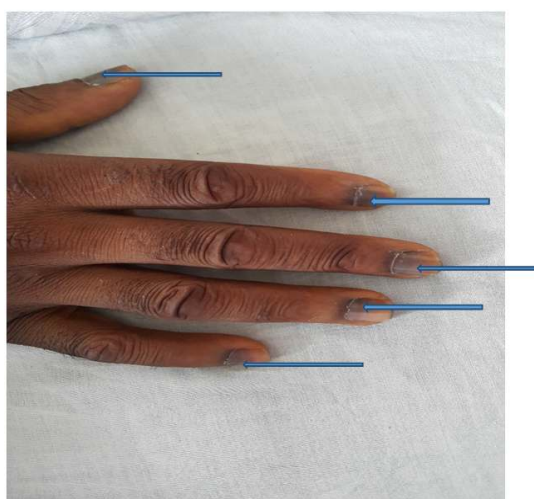


Fig. 1. Showing melanonychia involving half the length of nails of all fingers
Arrows indicating the Transverse Melanonychia

3. DISCUSSION

Nails are cutaneous adnexal structures that form an integral component of the digital tip. It is a highly functional part of both toe and fingers, primarily involved in protecting the finger and toe tip. The structures that define and produce the nail (nail plate) include the matrix, the proximal nail fold, the eponychium, the paronychium (lateral nail fold), and the hyponychium. The nail plate is composed of hard, keratinized, squamous cells that are loosely adherent to germinal matrix but strongly attached to the sterile matrix. Drug induced nail changes result from toxicity to the matrix, nail bed, periungual tissues or digital blood vessels [5] and melanin deposition. Chromonychia as one of the chemotherapy induced nail change refers to an abnormality in color of the substance or the surface of the nail plate or subungual tissues.

Chromonychia involves melanonychia (melanin deposition), leukonychia, and erythronychia. Melanonychia is the most common as seen in this case report. Most nail changes following antineoplastic agents are tolerable but can also be more devastating and require intervention [2]. Melanonychia is tolerable and does not require any medical intervention, however it causes anxiety for the patient which was expressed by this patient. The severity of changes depends on the drug, doses, duration and frequency of treatment though environmental factors also has influence on the severity [3]. A genetic predisposition is thought to contribute to its development. Melanonychia could be longitudinal, transverse or total depending on the pattern of streaks seen on the nail bed but the longitudinal pattern appears most common of the three [6]. The common etiologies of longitudinal melanonychia include acanthosis nigricans, Addison's disease, Vitamin B12 deficiency, Psoralen and Ultraviolet A radiation (PUVA) [7]. The transverse melanonychia is uncommon. Transverse melanonychia was observed in our patient. Medications such as cyclophosphamide, adriamycin, vincristine, hydroxyurea, etoposide, bleomycin, dacarbazine, 5-fluorouracil and methotrexate, [7] and antimalarials notably amodiaquine, quinacrine, chloroquine have been implicated. Antivirals (zidovudine, lamivudine) may cause both transverse and longitudinal bands, with multidrug chemotherapy causing the majority of the former. Melanonychia was observed after the first dose of cyclophosphamide and vincristine though patient also had daunorubicin. Systemic examination and laboratory investigations did not suggest any systemic disorder that could result in melanonychia. The change was probably due to combined effect and cumulative effects of the drugs. Cyclophosphamide has been reported to cause slate grey to black pigmentation sometime associated with pains discomfort with varied pattern [8]. Mechanism of melanonychia is not well understood. Photosensitivity and direct toxicity to the nail matrix or nail bed and focal stimulation of nail-matrix melanocytes have been hypothesized [8,9]. Melanonychia commonly starts from the proximal part to the distal end of the nails; this is because there are more active melanocytes in the distal end of the nail matrix.

Longitudinal melanonychia occurs as a result of two mechanisms, one being melanocyte activation and the other mechanism is melanocyte hyperplasia [10]. In melanocytic activation, there is increased melanin deposition

in the nail matrix and plate without the concurrent increase in the number of melanocytes [11] but in melanocytic hyperplasia, there is increased melanin deposition as a result of increased in the number of melanocytes in the nail matrix though both benign and malignant forms exist [6] Transverse pigmentation of nail probably develops due to a direct toxic effect on the nail matrix [12]. Toxicity result in activation of the corresponding melanocytes.

Most report of pigmentation involves both fingernails and toes though the nail changes may involve all or some nails [1,13]. In this patient, the unusual distribution of melanonychia sparing the toe nail has been explained by the variability in the rate of nail growth of the hands and feet with the toe nails growing slower. Melanonychia was observed with the first dose of cyclophosphamide (1 gm) and vincristine (2 mg) in our patient, though typically unusual, pigmentation has been observed to occur from 10 days to 26 weeks after initiation of therapy and doses ranged from 1.2 to 12.5 g (14). This nail discoloration was asymptomatic and no treatment was given. On withdrawal of drugs, clearing of the nail pigmentation usually proceed in a fashion similar to the way to it started [2,14]. Patient should however be counseled prior to commencement of chemotherapy of possible nail changes; this is to allay anxiety in the patient. Melanogenesis in the nail matrix melanocytes varies with the intensity of cutaneous pigmentation and hence is more common in darkly pigmented people [15]. However few report have been from the sub-Saharan African population.

However, clinician should rule out other more serious conditions such as naevus, subungual melanomas and pigmented cell carcinoma which could mimic this disorder. These other conditions would require biopsy. When other serious conditions are suspected histopathologic diagnosis remains the gold standard, though dermatoscopy might be helpful. If no biopsy is taken, clinical follow-ups are necessary at short intervals [16].

4. CONCLUSION

Melanonychia secondary to chemotherapy on the nails could occur at any stage of chemotherapy and is not dose dependent. The distribution does not seem to follow any pattern. Genetic predisposition rather than race maybe more important in the development of melanonychia.

CONSENT

It is not applicable.

ETHICAL APPROVAL

It is not applicable.

COMPETING INTERESTS

Authors have declared that no competing interests exist.

REFERENCES

1. Gilbar P, Hain A, Peereboom VM. Nail toxicity induced by cancer chemotherapy. *J Oncol Pharm Pract.* 2009;15(3):143-155. DOI: 10.1177/1078155208100450 (Epub 2009 Jan 26)
2. Issaivanan M, Khairkar PH. Doxorubicin induced melanonychia. *Indian Pediatr.* 2003;40:1094-1095.
3. Haneke E. Surgical anatomy of the nail apparatus. *Dermatol Clin.* 2006;24(3):291-296.
4. Gupta A, Parakh A, Dubey AP. Chemotherapy induced nail changes. *Indian J Dermatol.* 2008;53(4):204-205.
5. Susser WS, Whitaker-Worth DL, Grant-Keis JM. Mucocutaneous reactions to chemotherapy *J. America Acad Dermatol.* 1999;40(3):367-398.
6. Jefferson J, Rich P. Melanonychia, review article. *Dermatology Research and Practice.* 2012;2012:952186.
7. Das A, Podder I, Kumar D, Ghosh A, Shome K. Imatinib-induced transverse melanonychia: An unusual presentation. *Indian J Dermatol.* 2015;60(4):412-413. DOI: 10.4103/0019-5154.160500
8. Kumar S, Dixit R, Karmakar S, Paul S. Unusual nail pigmentation following cyclophosphamide containing chemotherapy regimen. *Indian Pharmacol* 2010;42(4): 243-244.
9. Karath SS, Gerpta A, Prahu M. melanonychia and mucocutaneous hyperpigmentation from hydroxyurea use for the treatment of essential thrombosis. *Singapore Med J.* 2014;55(1):e7-e8.
10. Giraldo WA, de la Puente Bujidos C. Longitudinal melanonychia associated with

- limited cutaneous systemic sclerosis. J Clin Rheumatol. 2014;20:118–119.
11. Andre J, Lateur N. Pigmented Nail Disorders. Dermatologic Clinics. 2006; 24(3):329-339.
 12. Hernández-Martín A, Ros-Forteza S, de Unamuno P. Longitudinal, transverse, and diffuse nail hyperpigmentation induced by hydroxyurea. J Am Acad Dermatol. 1999; 41:333–334.
 13. Dave S, Thappa DM. Peculiar pattern of nail pigmentation following cyclophosphamide therapy. Dermatol Online J. 2003;9(3):14.
 14. Quinlan KE, Janiga JJ, Barca R, Lim HW. Transverse melanonychia secondary to total skin electron beam therapy: A report of cases. Journal of the American Academy of Dermatology. 2005; 53(2 supplement):5112-5114.
 15. Rich P. Nail Surgery, Bologna JL, Jorizzo JL, Rapini RP, editors. Dermatology. 2nd edition. Chapter 149. New York, NY, USA Mosby. 2006;2260-2268.
 16. Dumke AK, Gina M, Goetze S, Schliemann S, Elsner P. Ethnic nail pigmentations and differential diagnoses. Hautarzt; 2016. [Epub ahead of print]

© 2016 Fasola and Aworanti; This is an Open Access article distributed under the terms of the Creative Commons Attribution License (<http://creativecommons.org/licenses/by/4.0>), which permits unrestricted use, distribution, and reproduction in any medium, provided the original work is properly cited.

Peer-review history:
The peer review history for this paper can be accessed here:
<http://sciedomain.org/review-history/16304>